

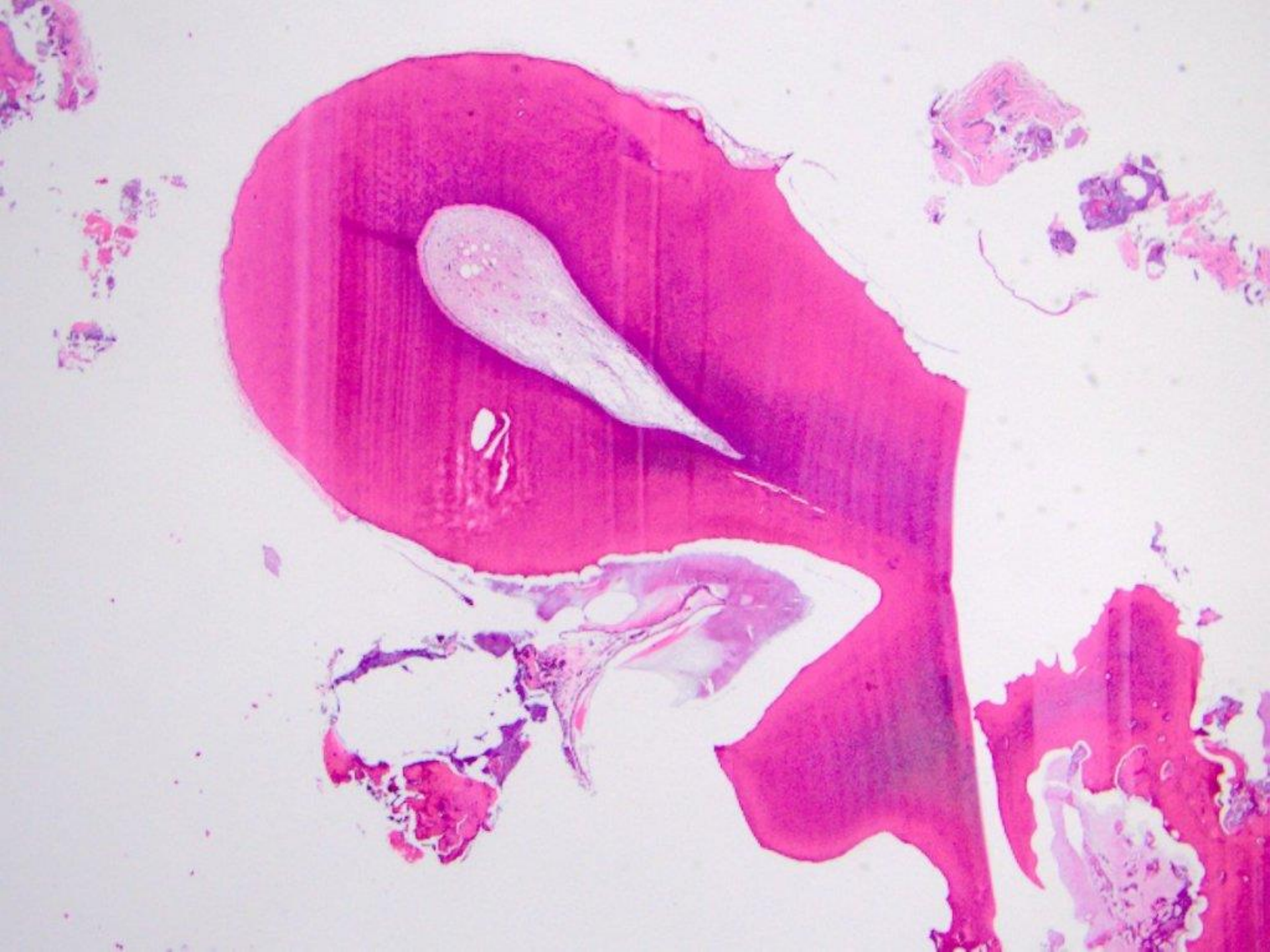
Oral Histopathology

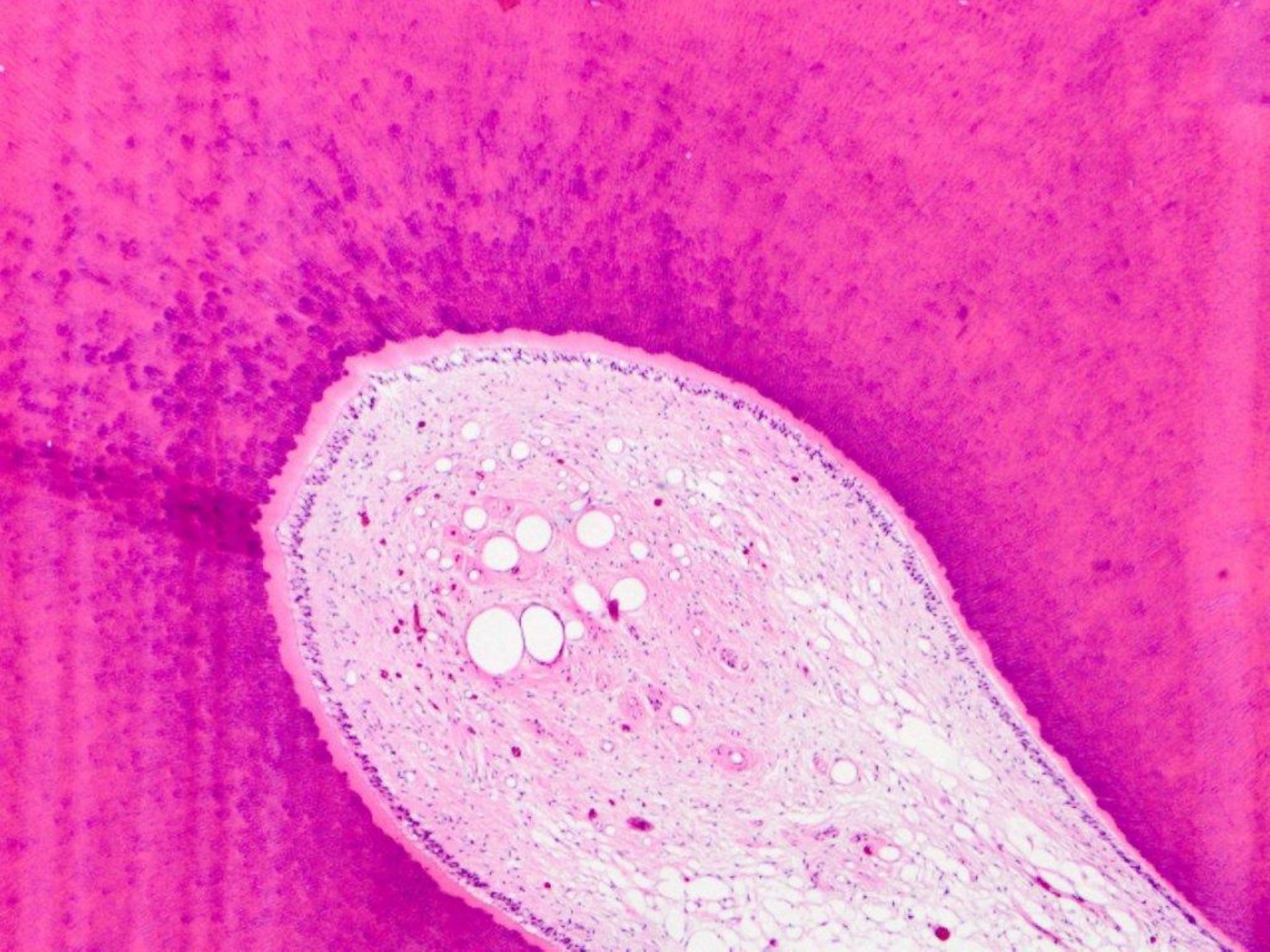Series 40

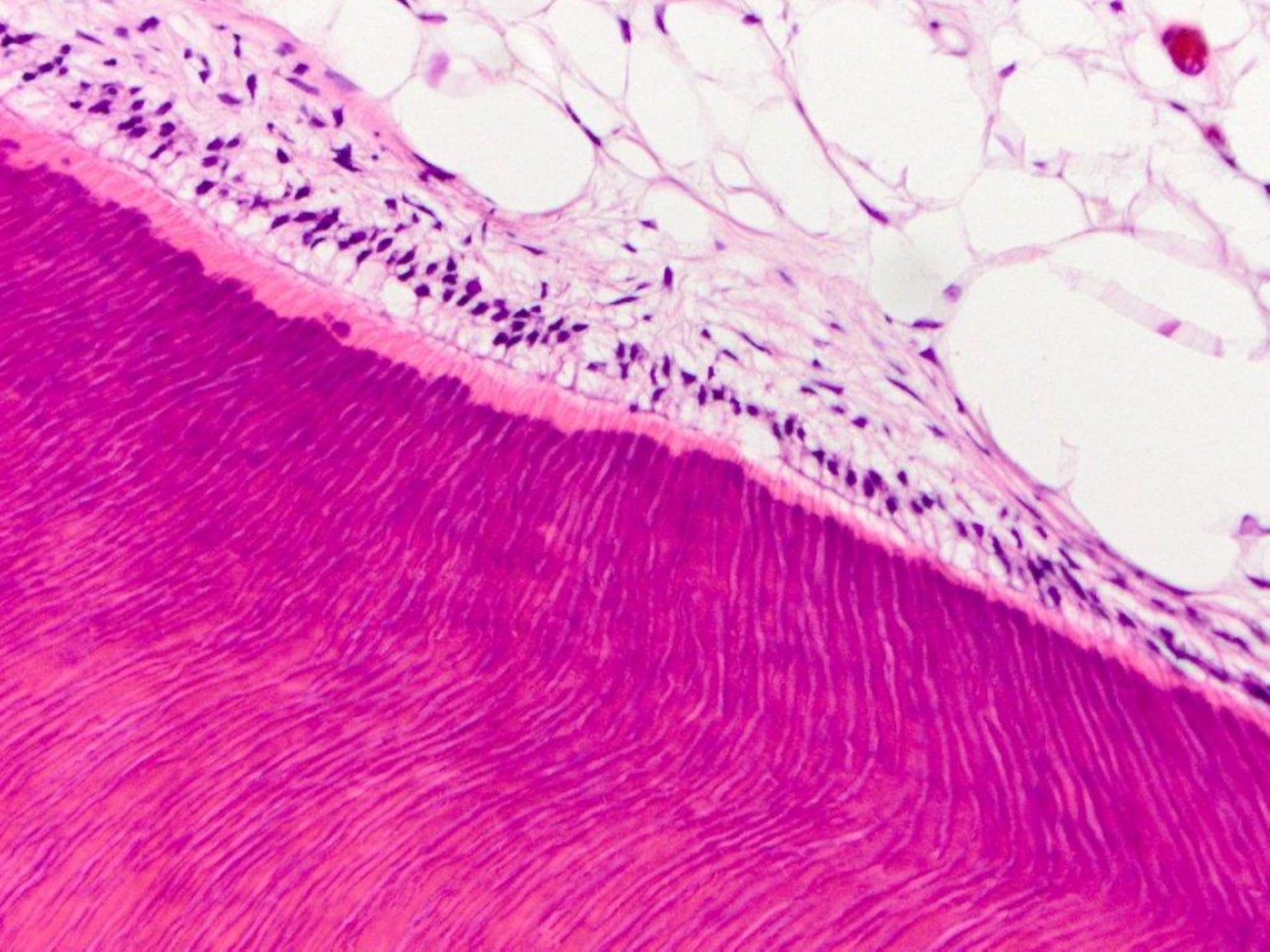
DAVID E. KLINGMAN, DMD

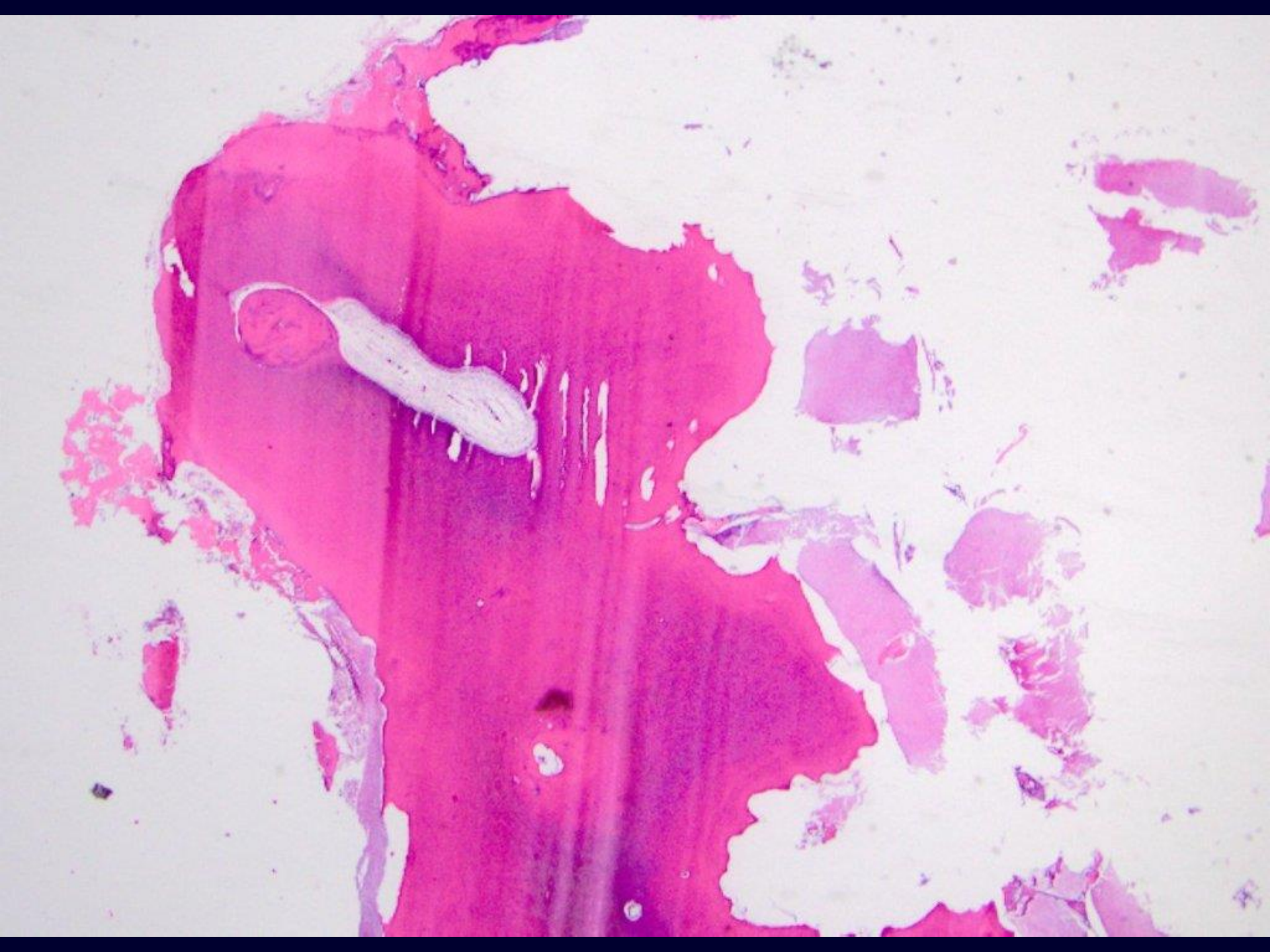
Diplomate, American Board of Oral and Maxillofacial Pathology

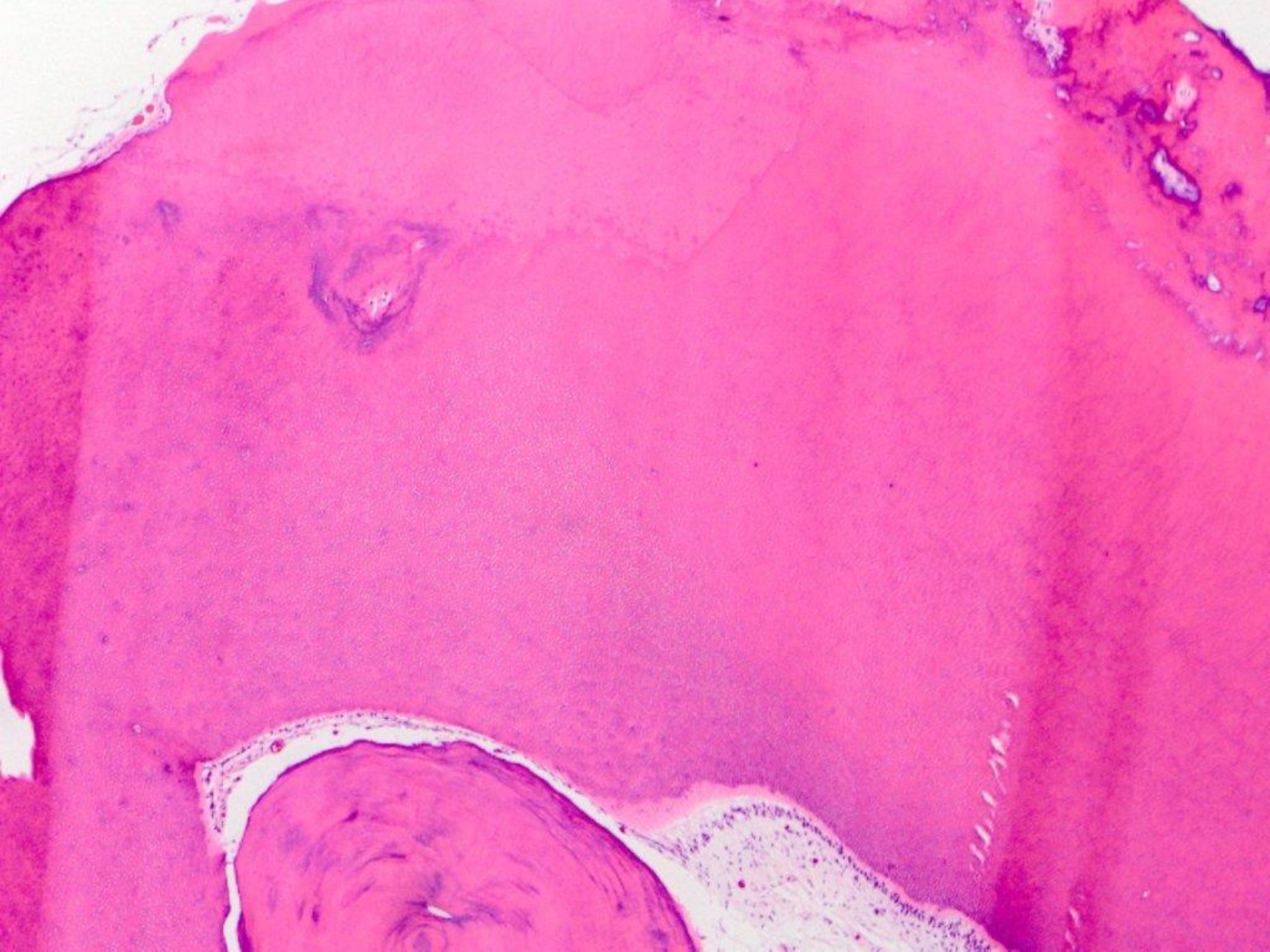Diplomate, American Board of General Dentistry

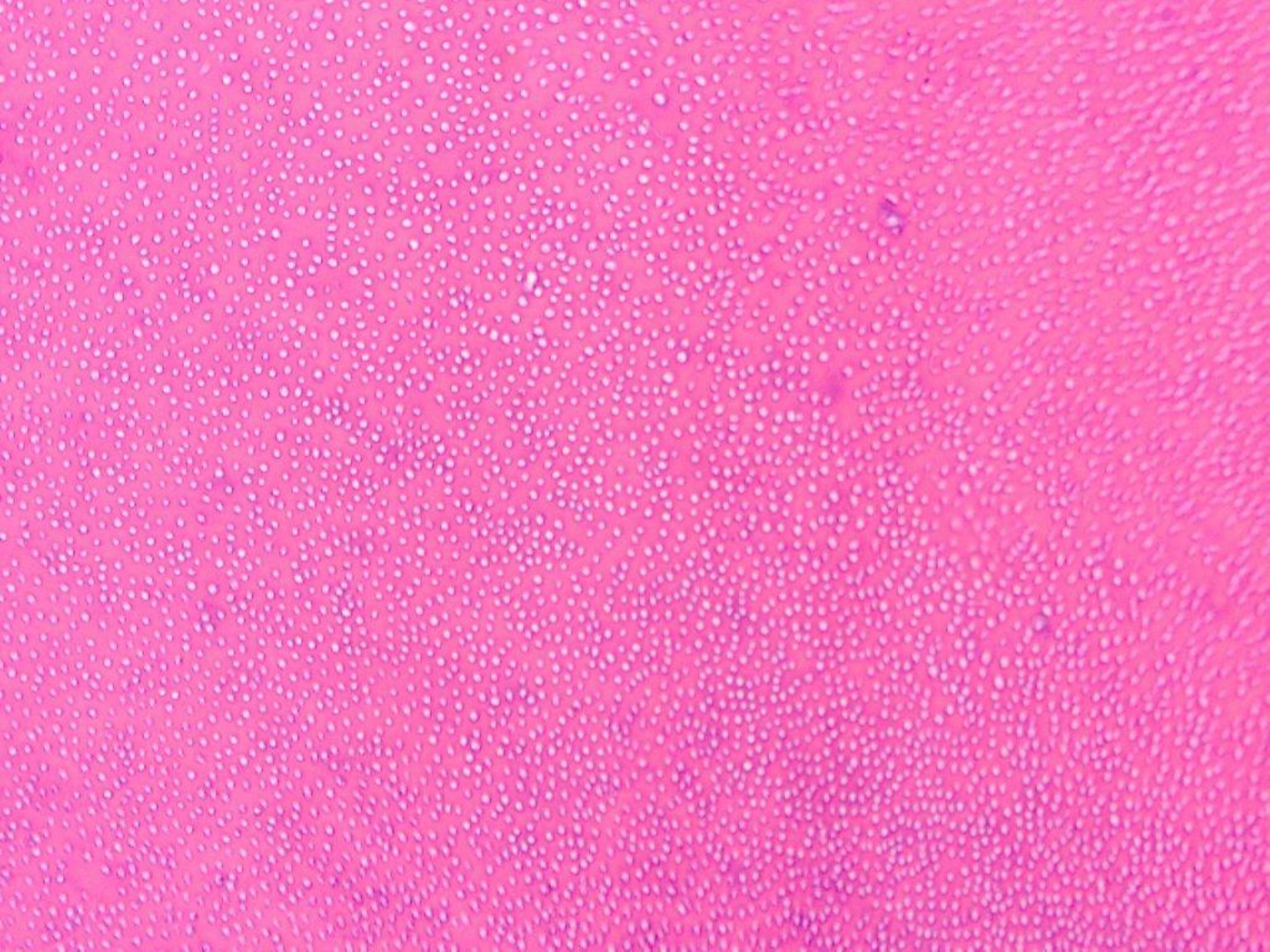


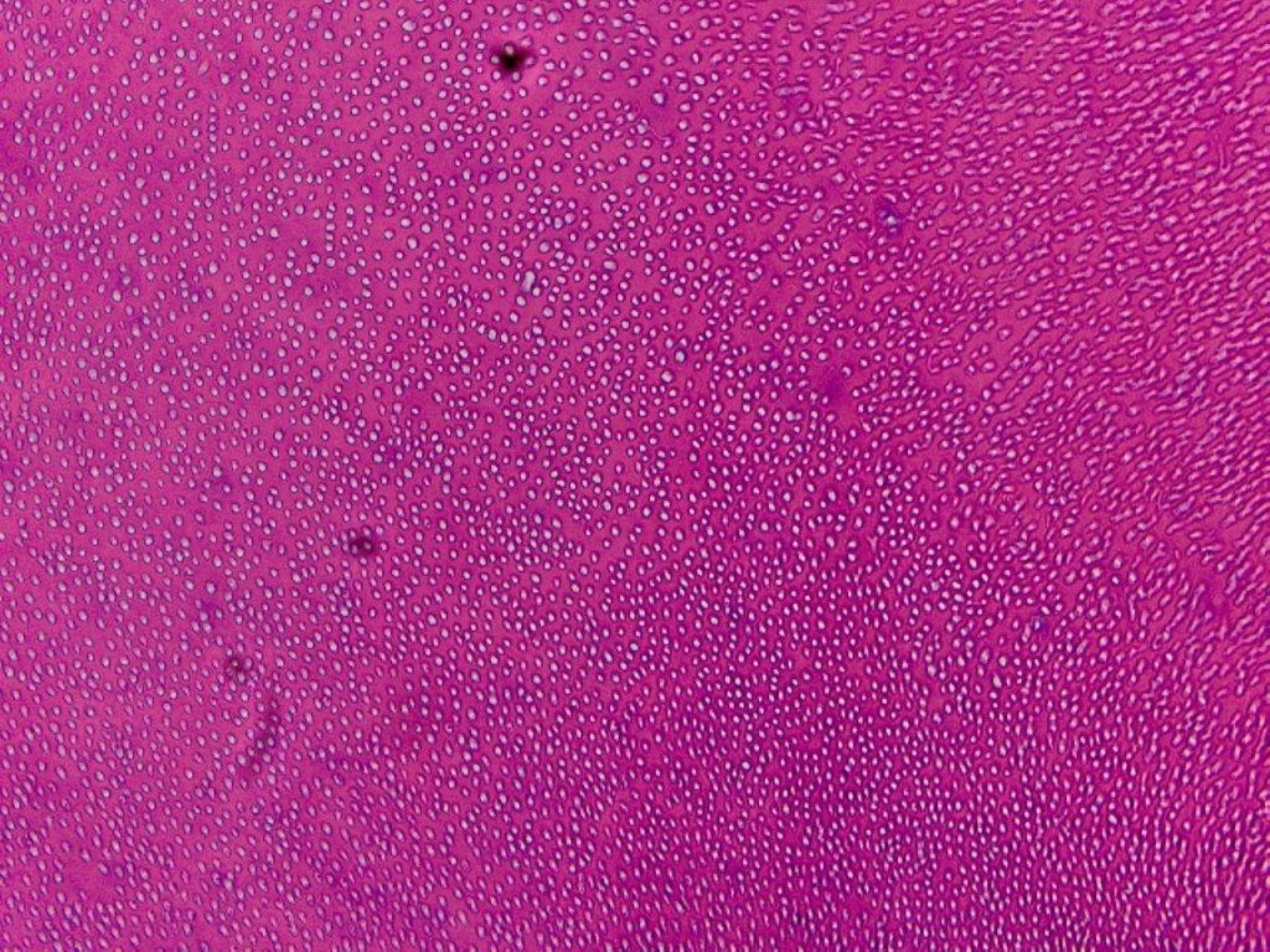


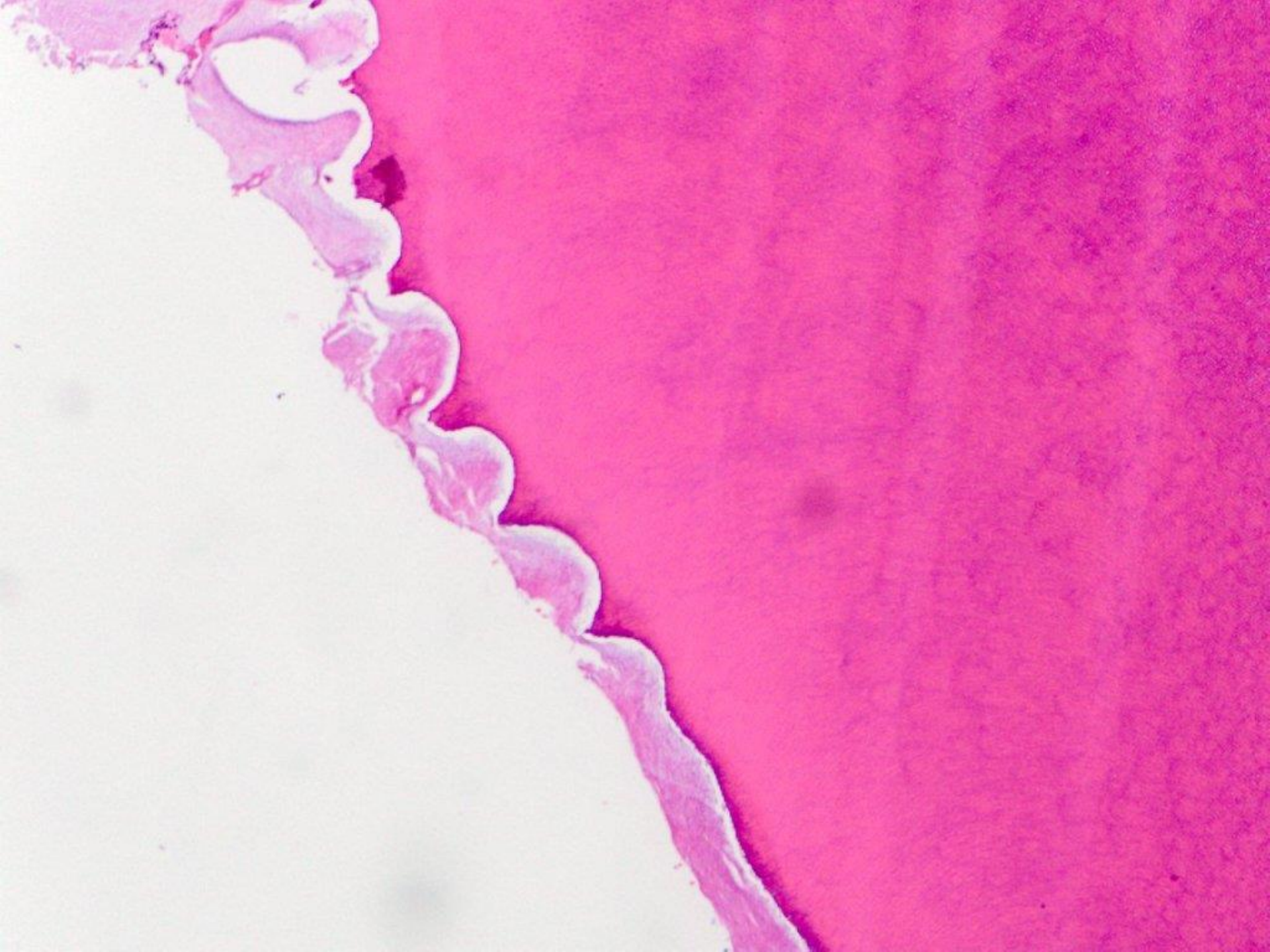


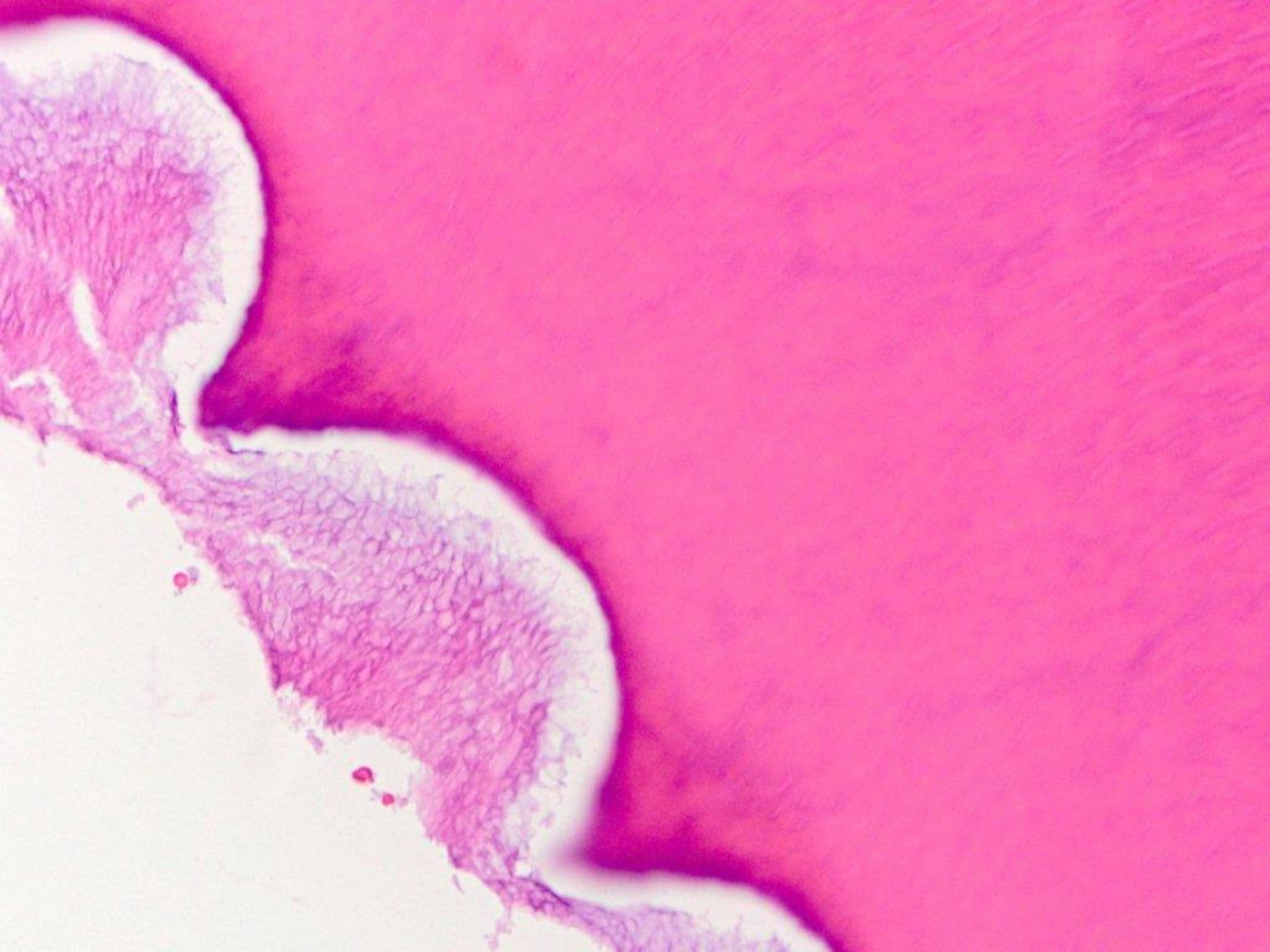


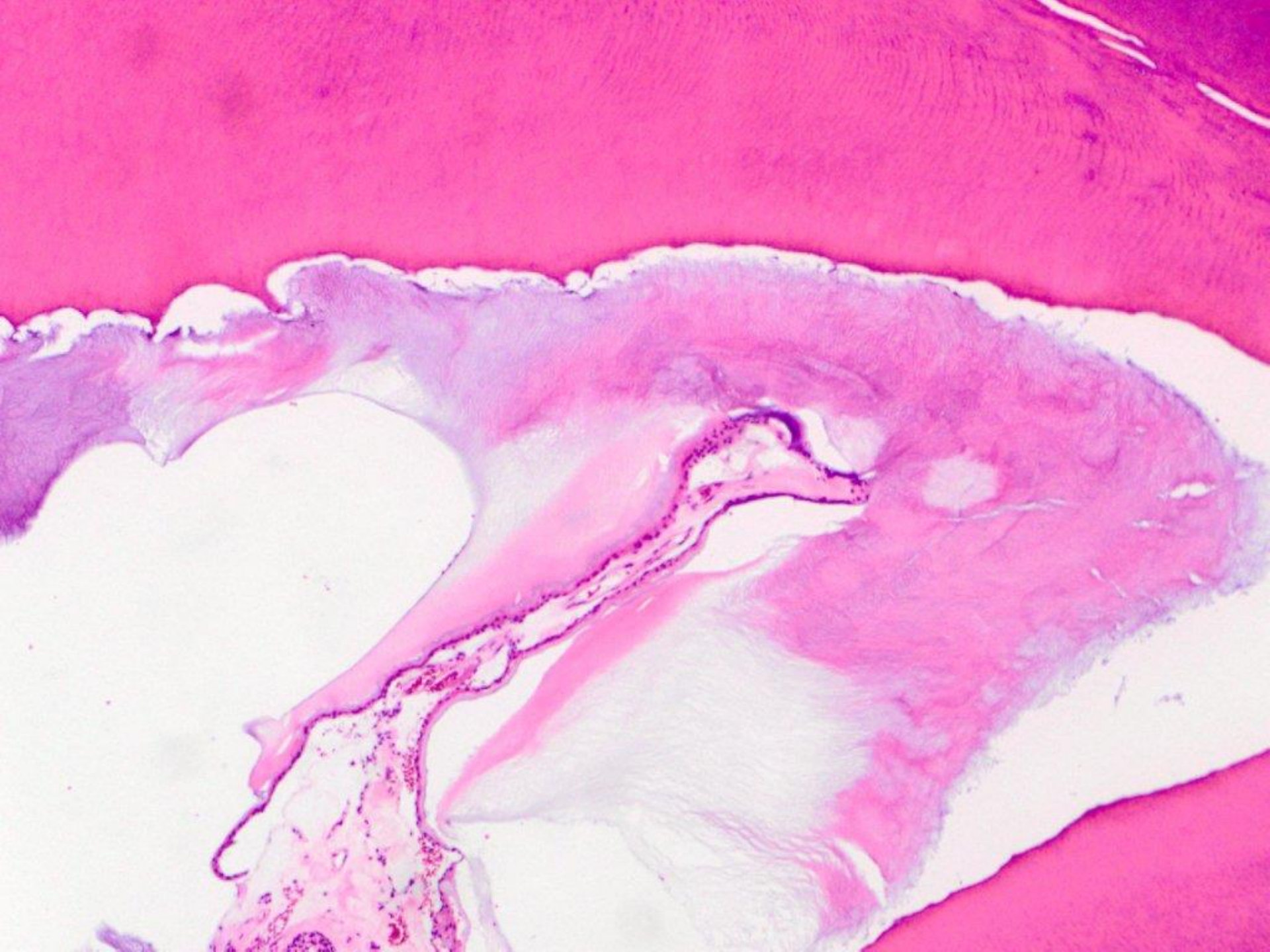


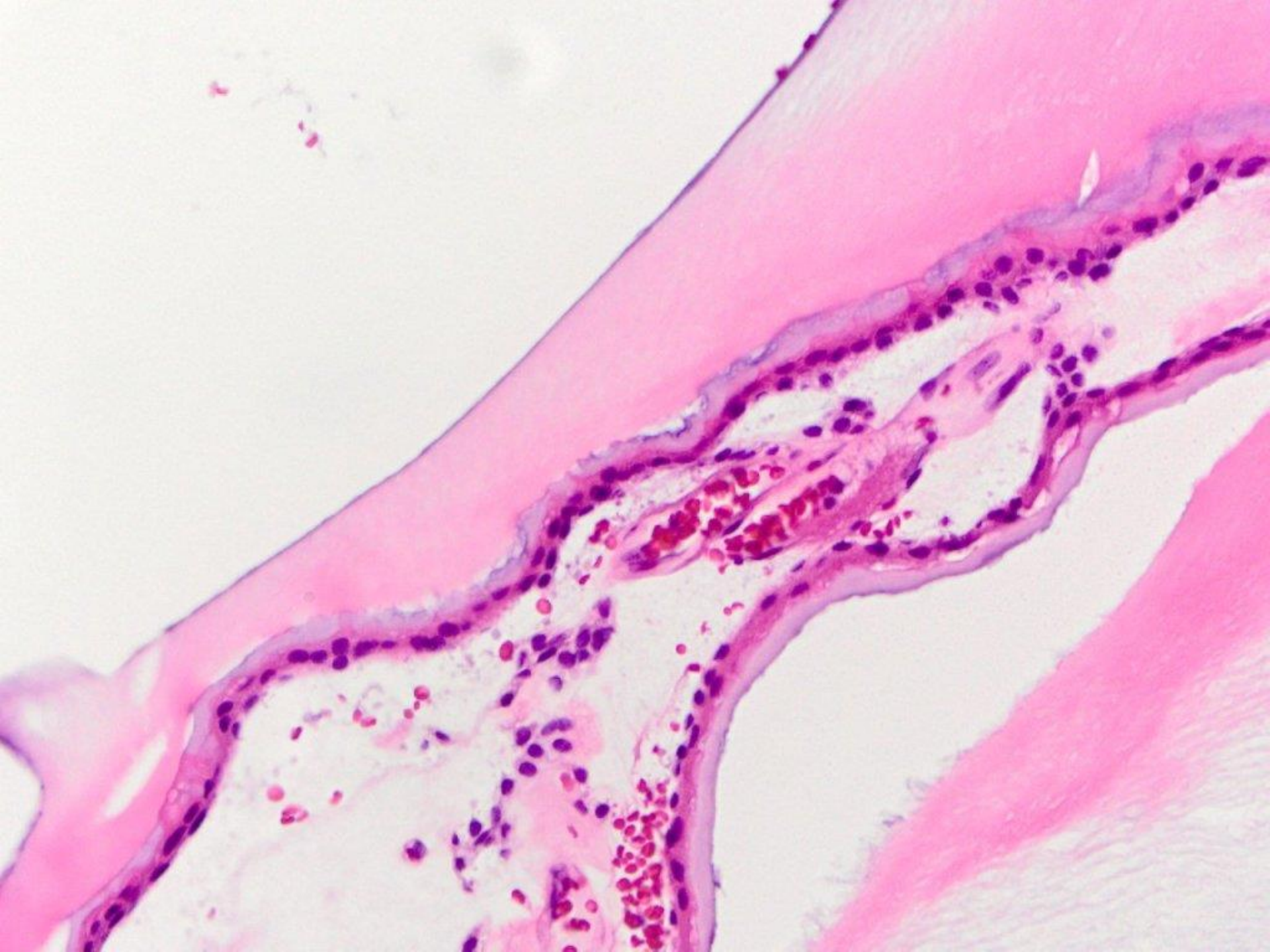


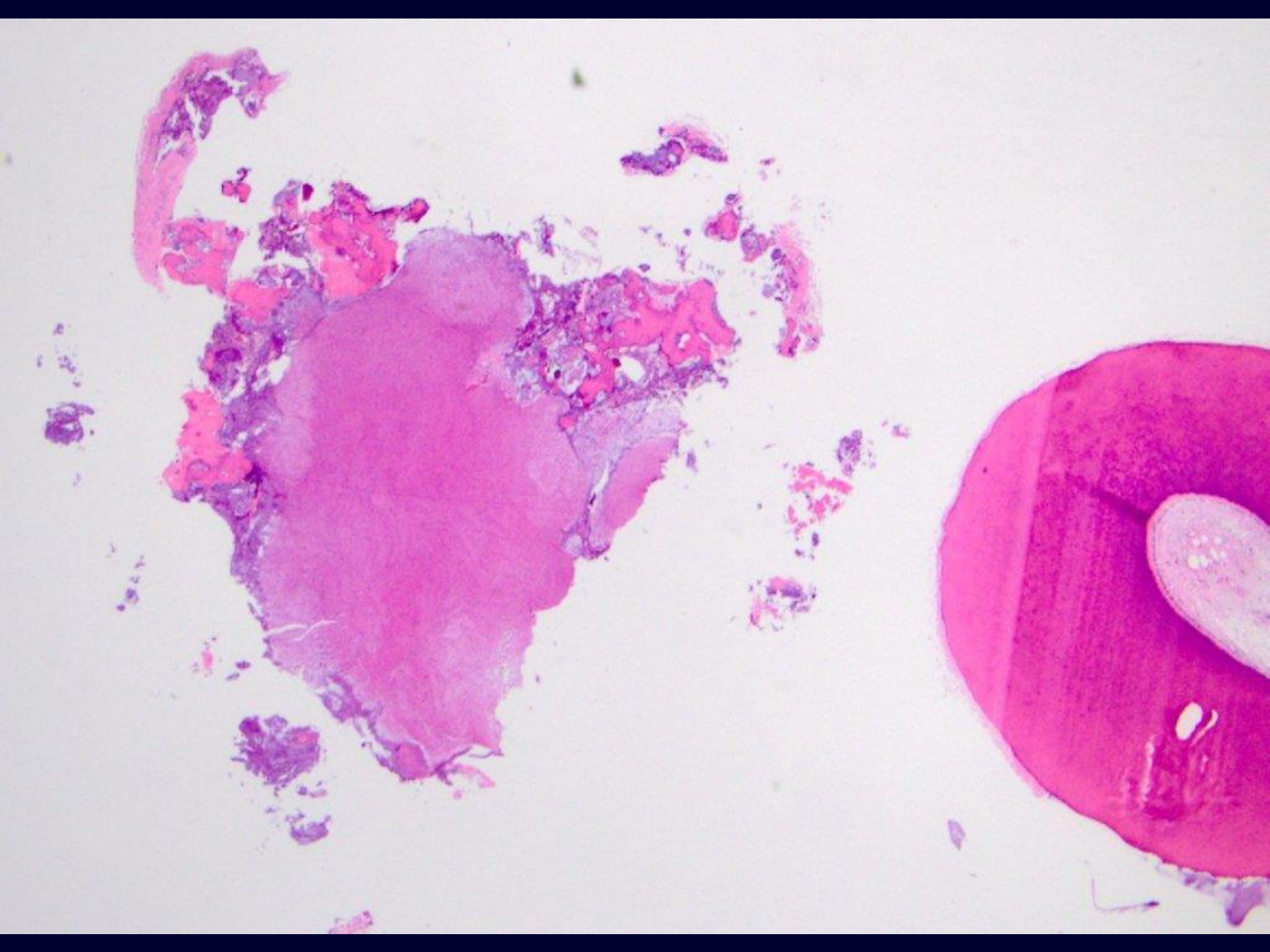


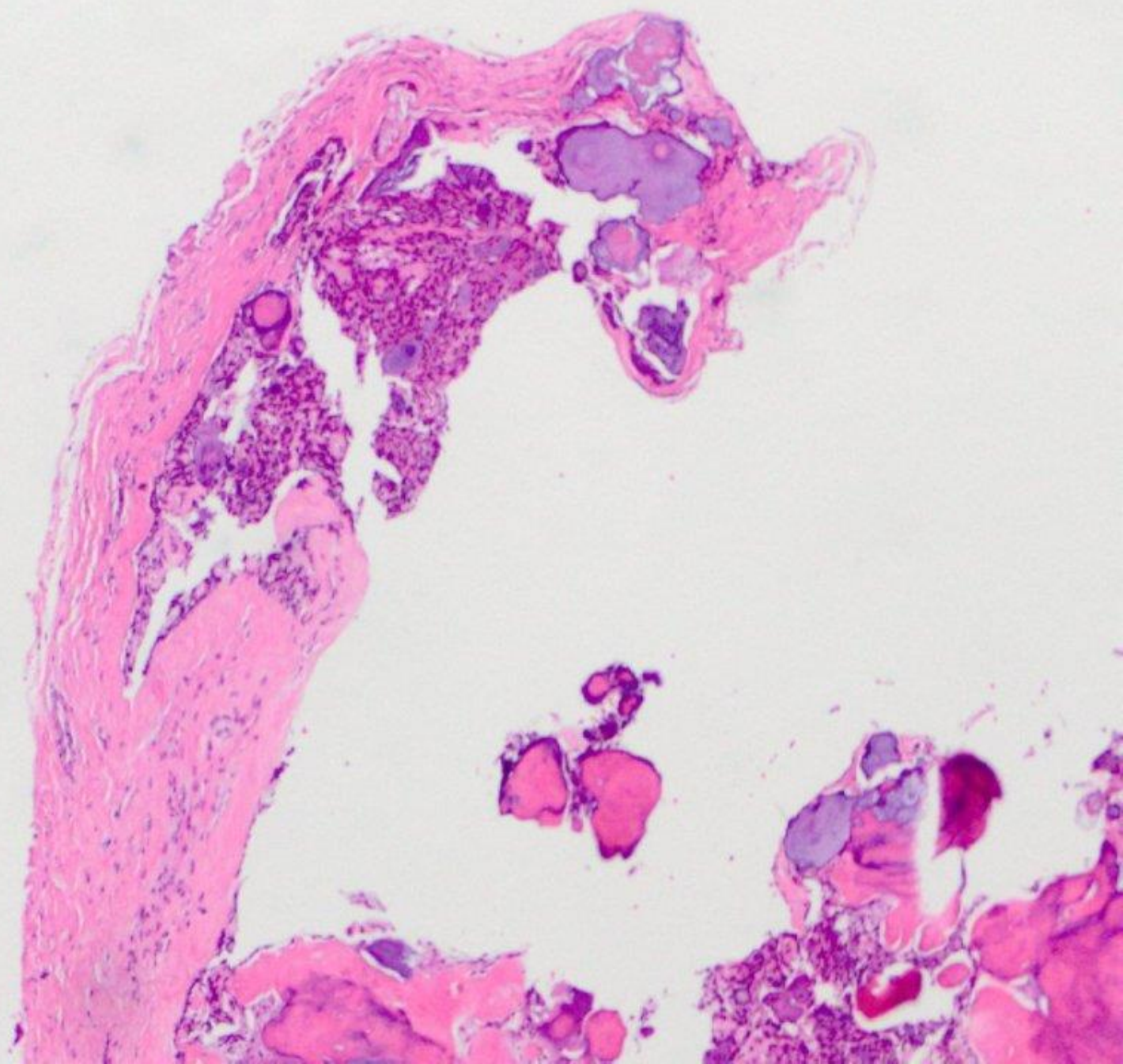


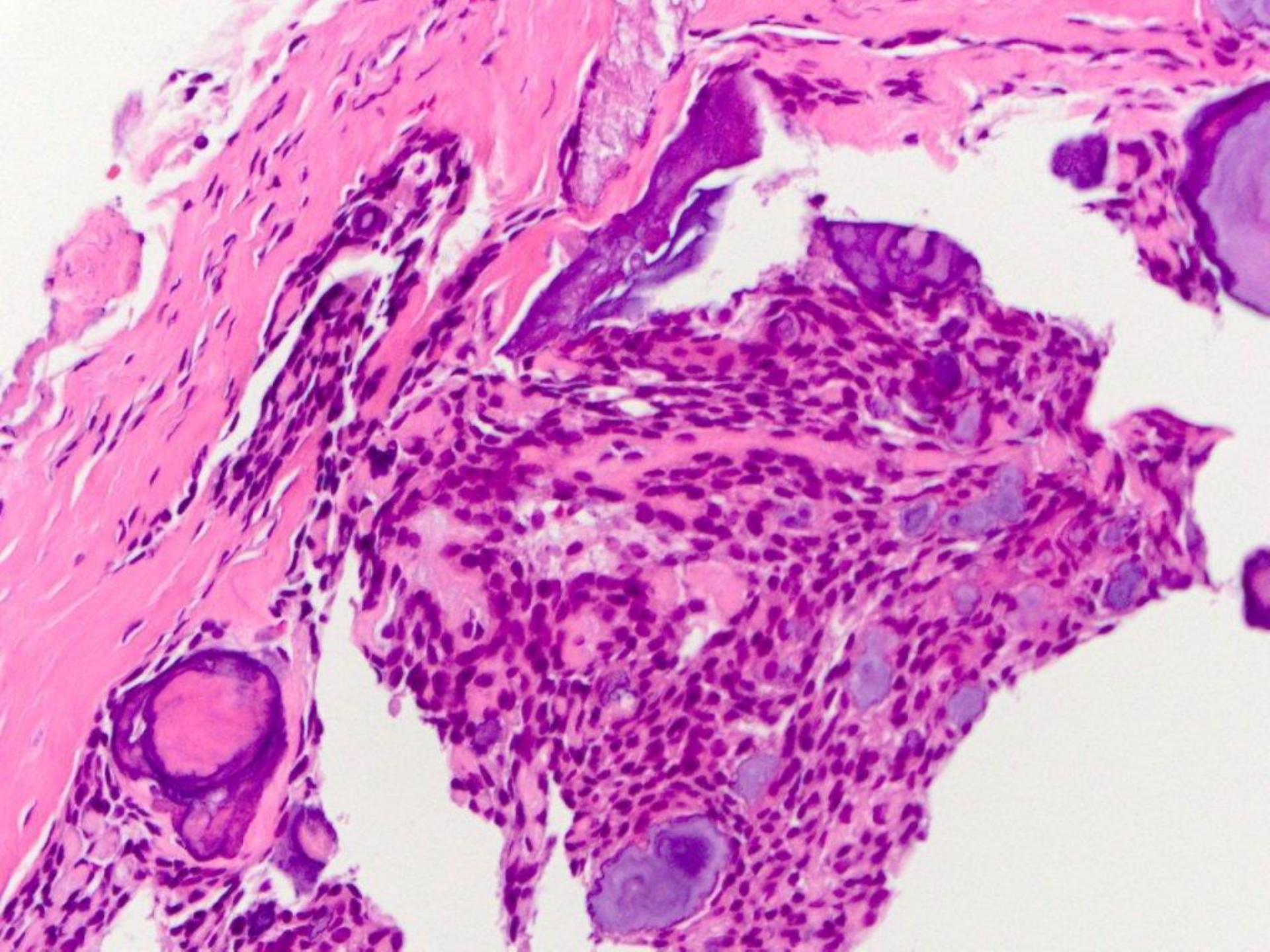


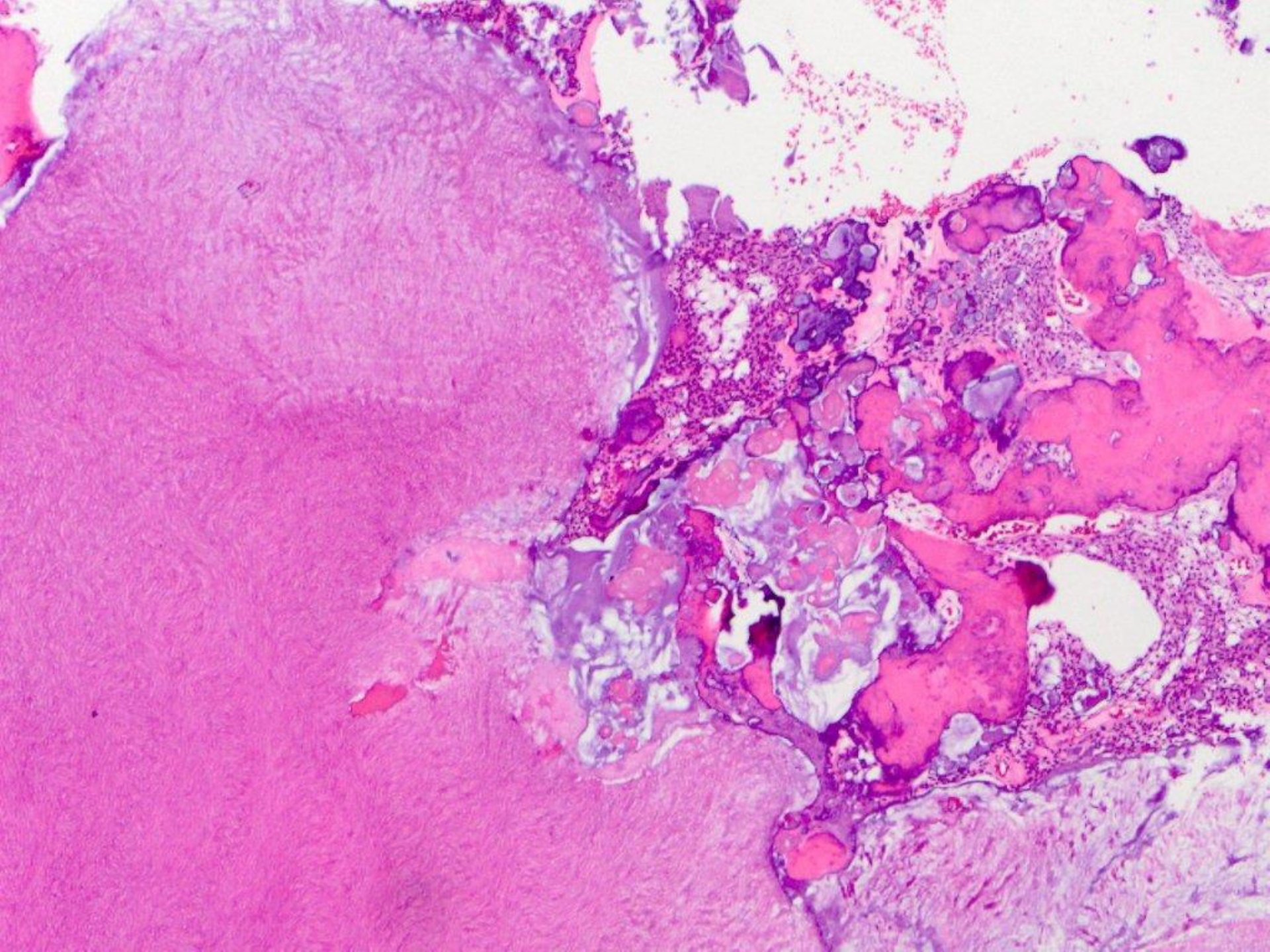


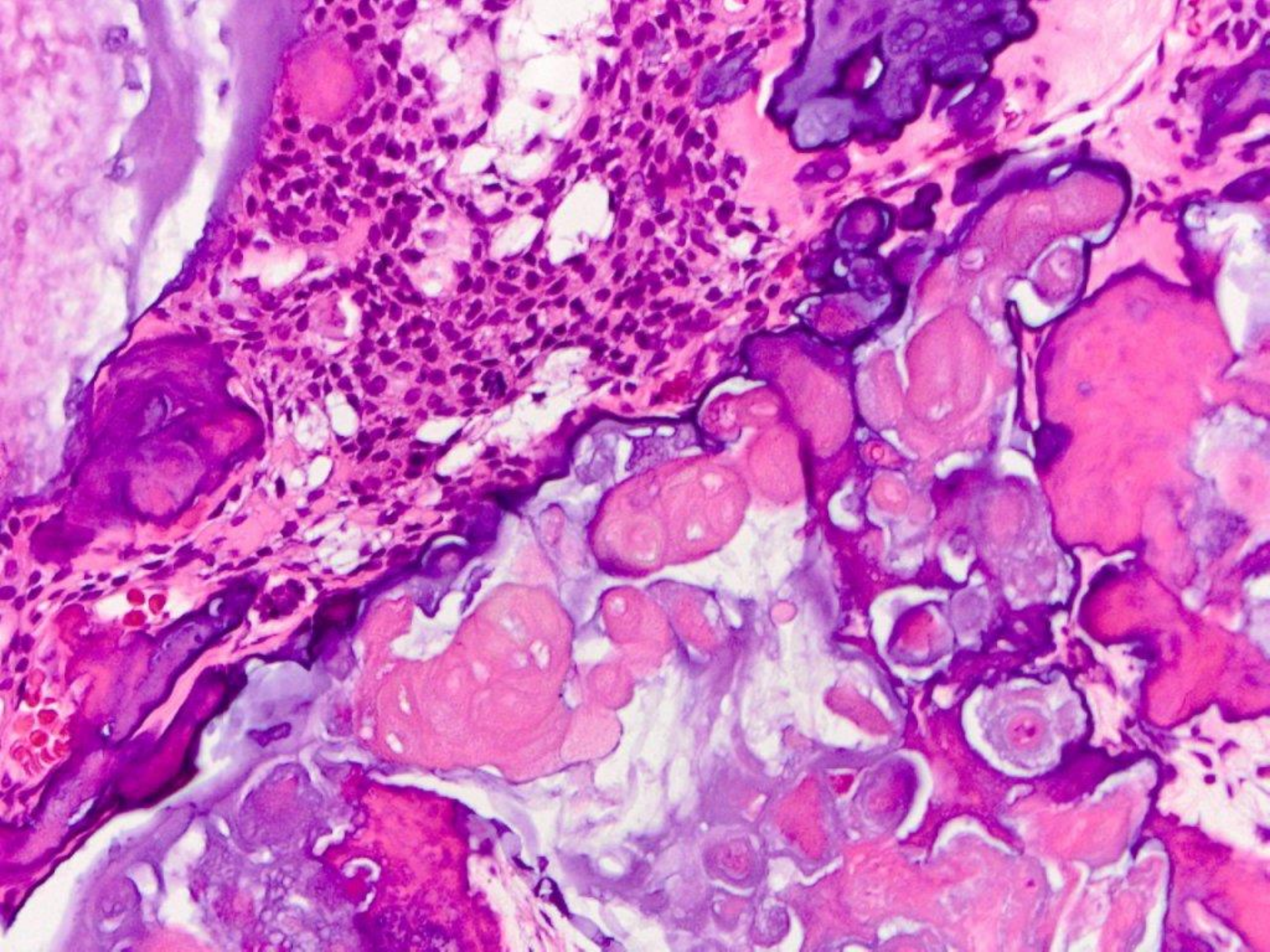


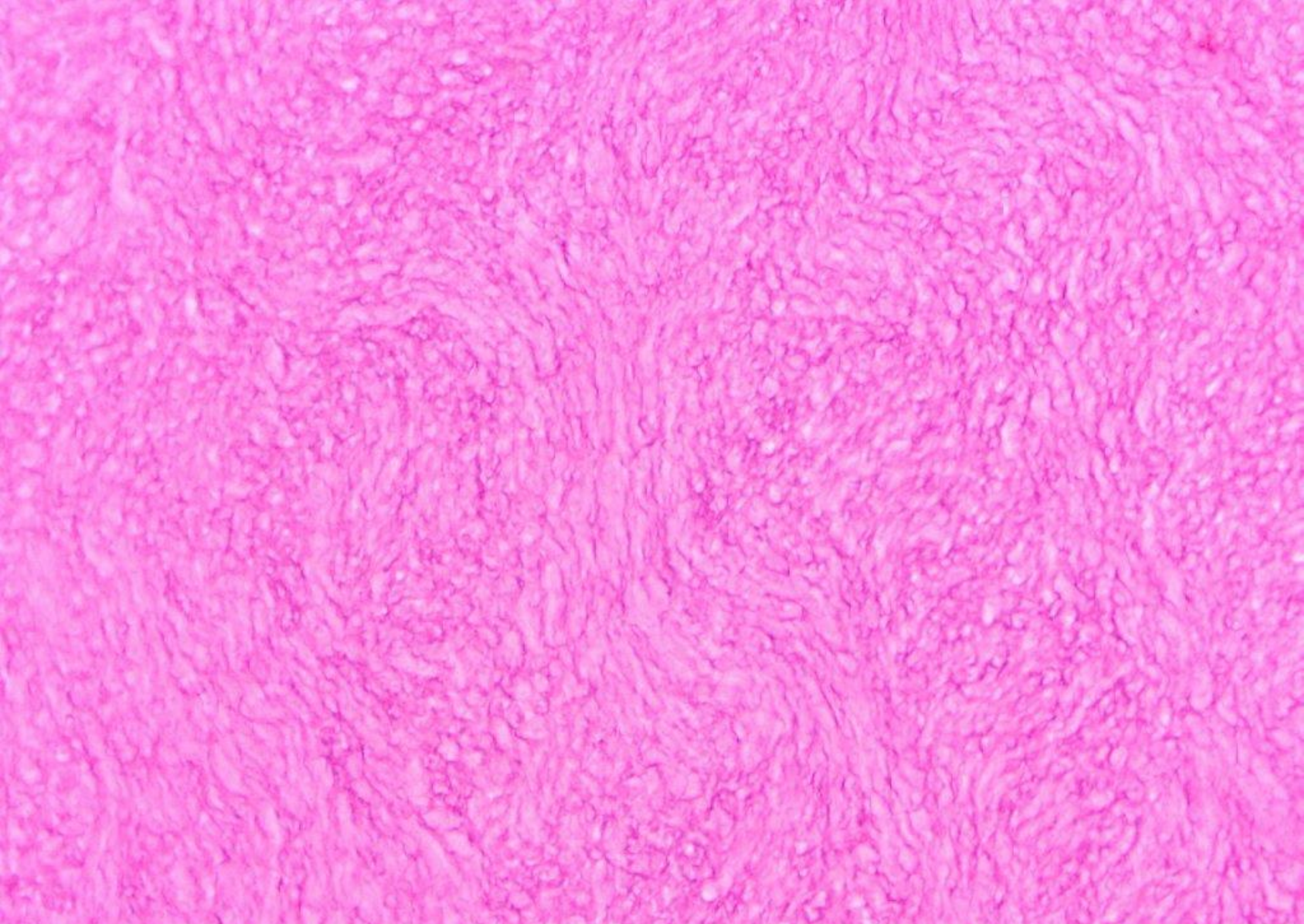




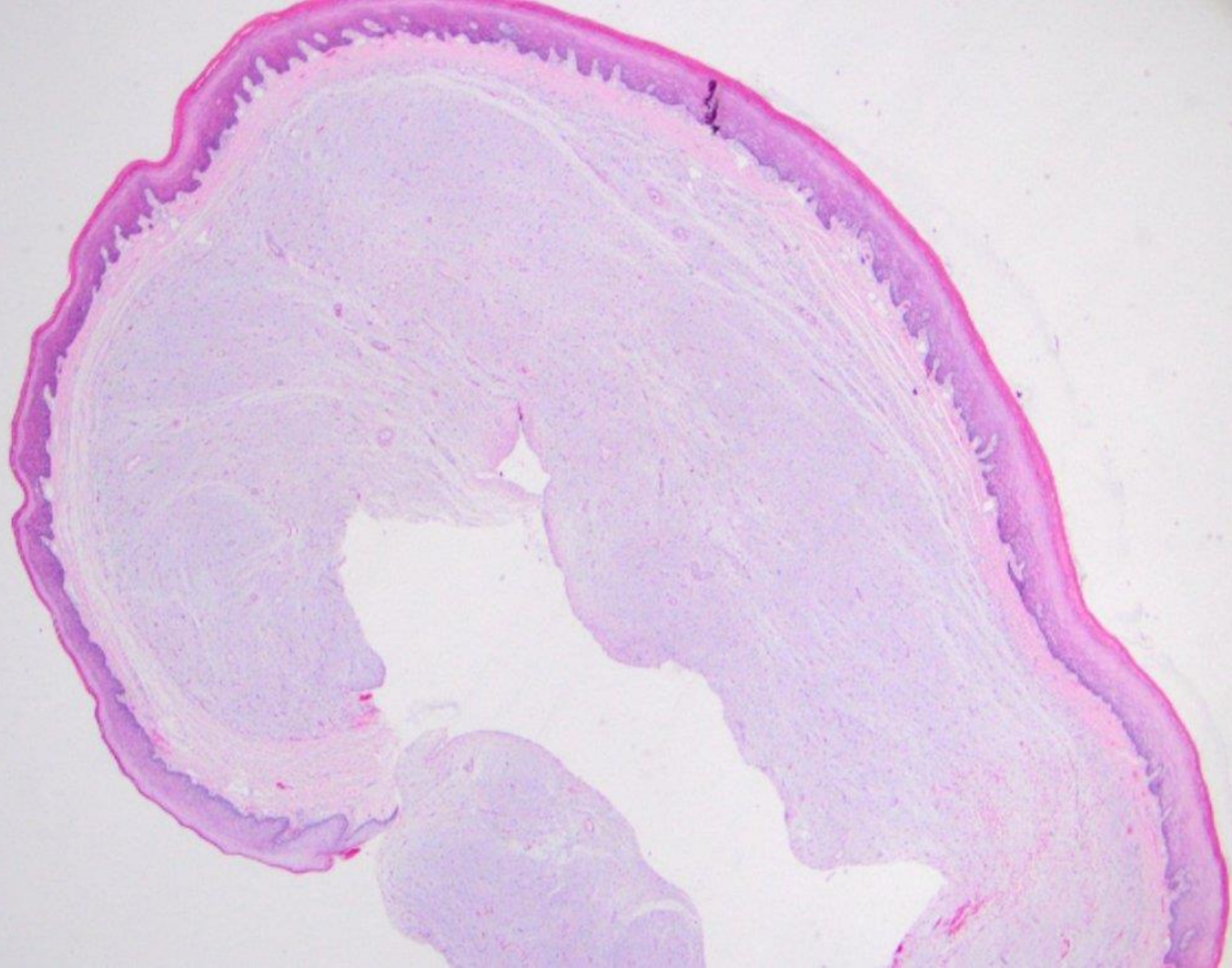


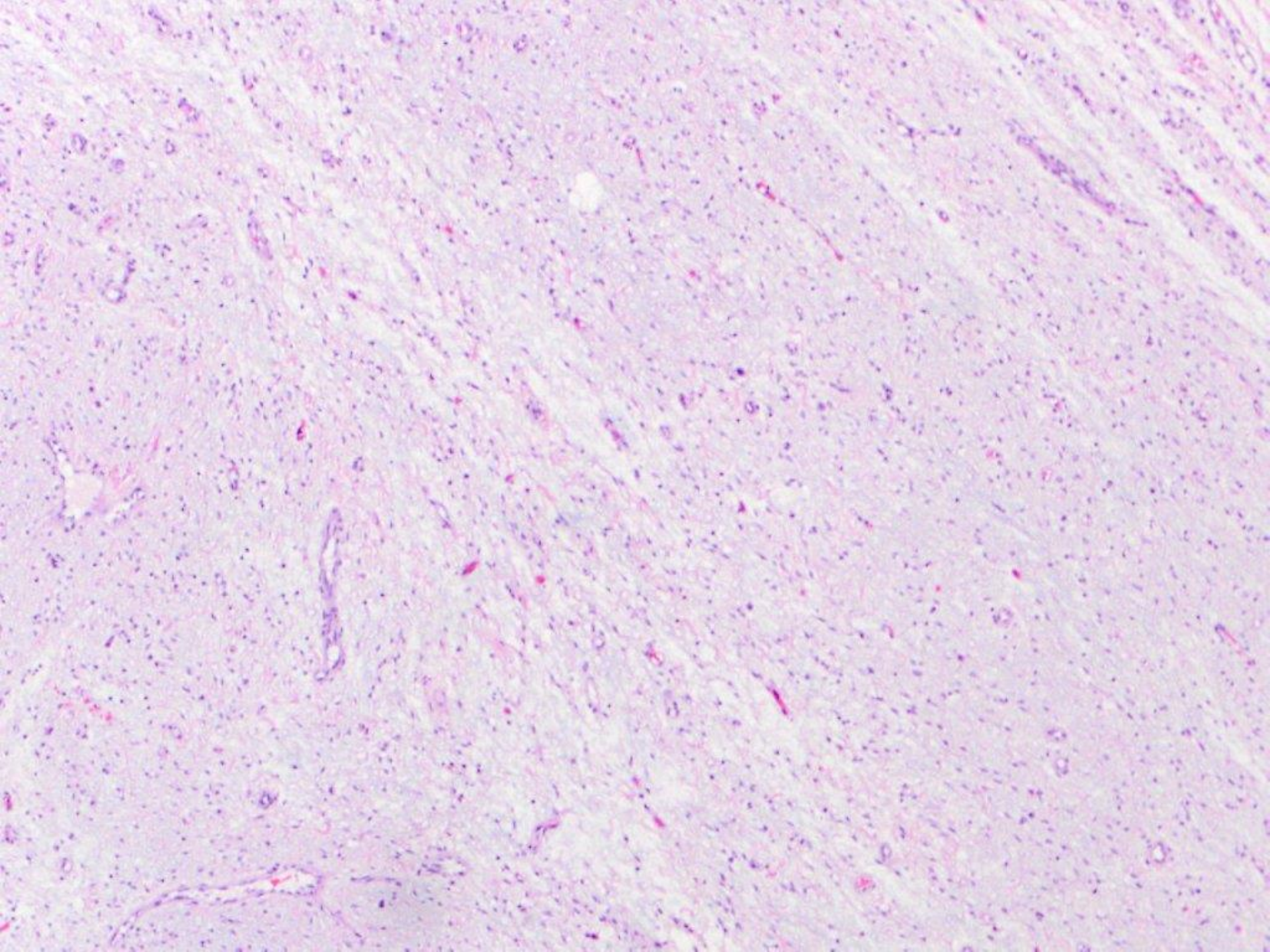


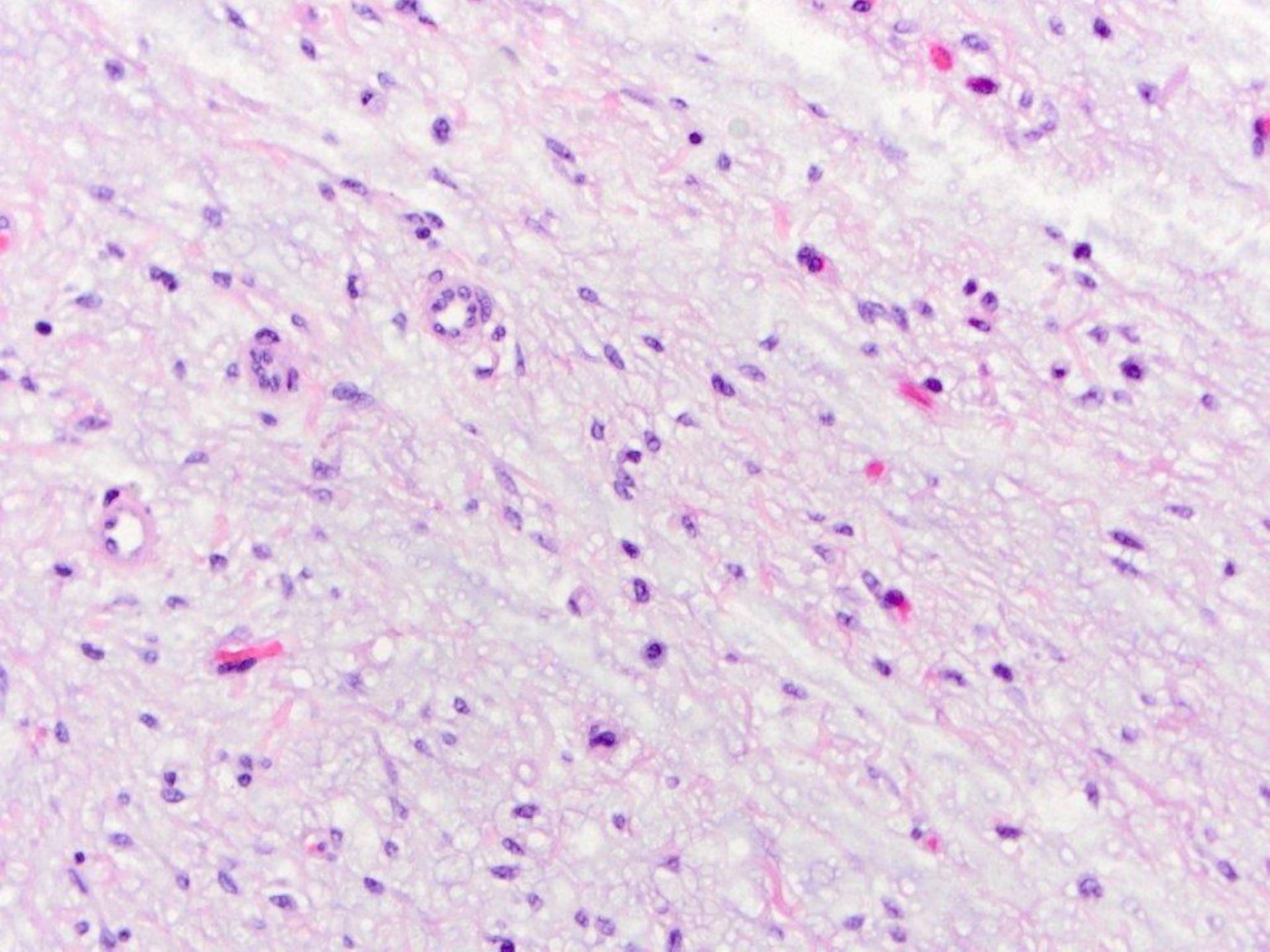


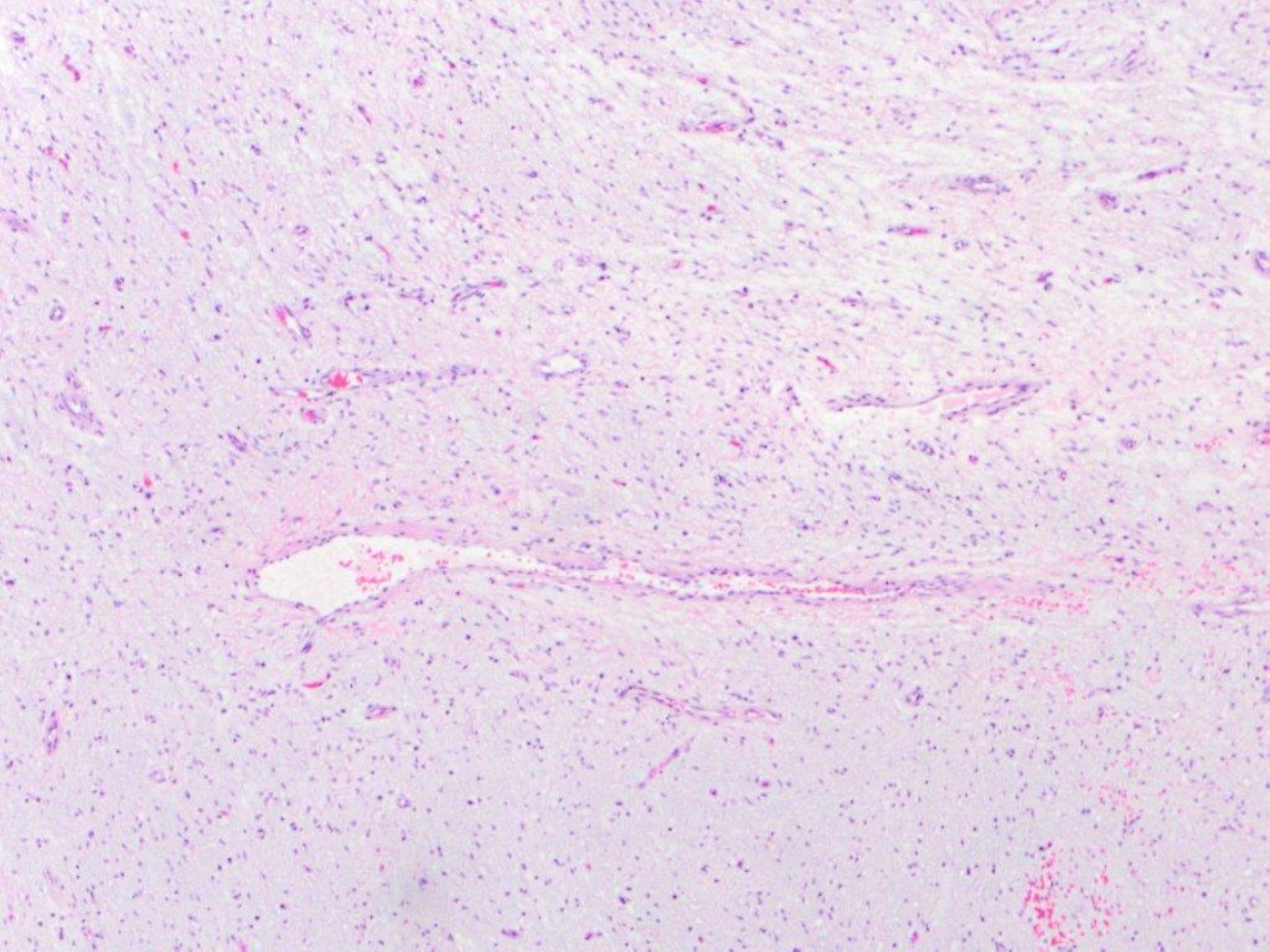


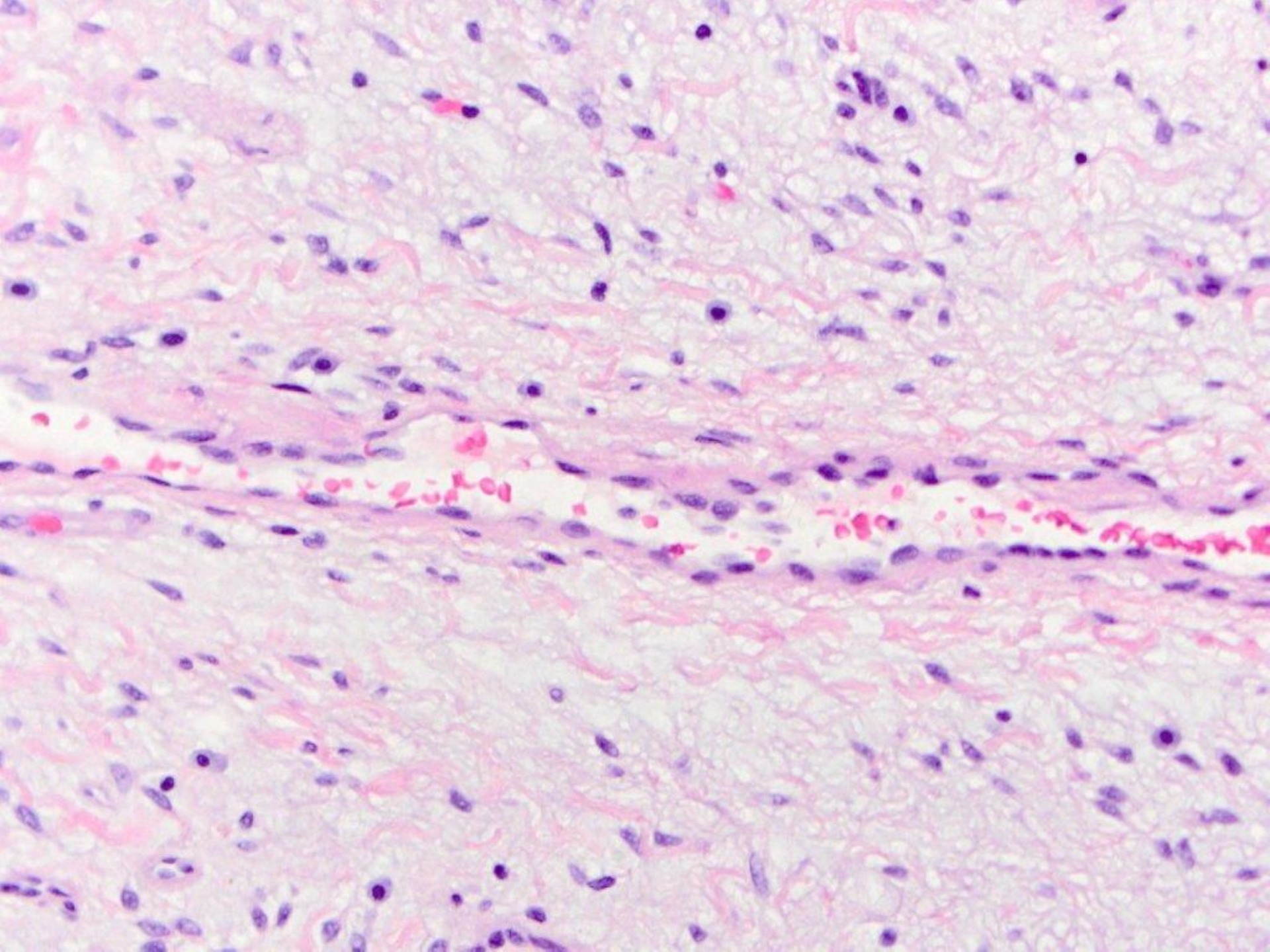
odontoma (complex)

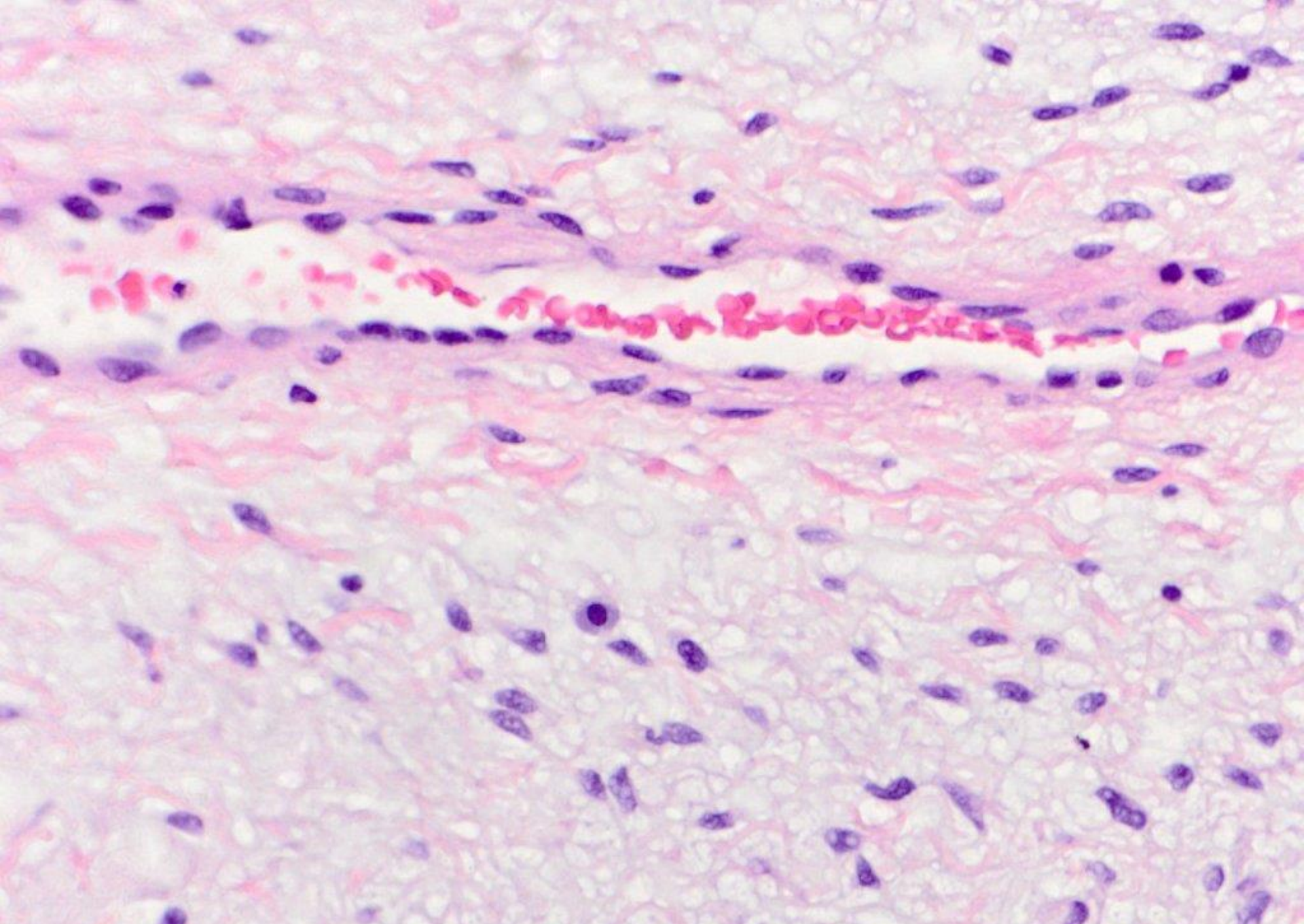




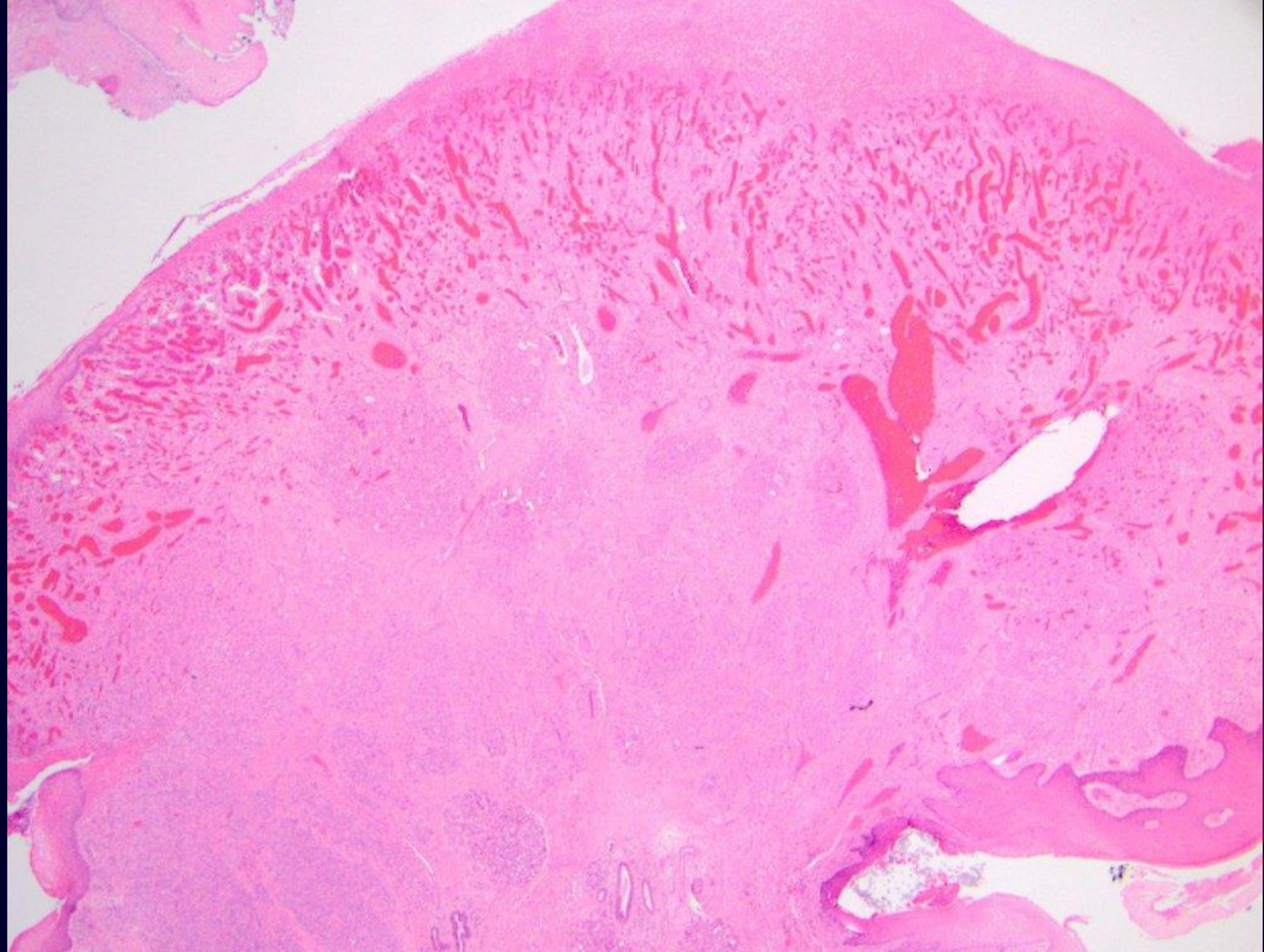


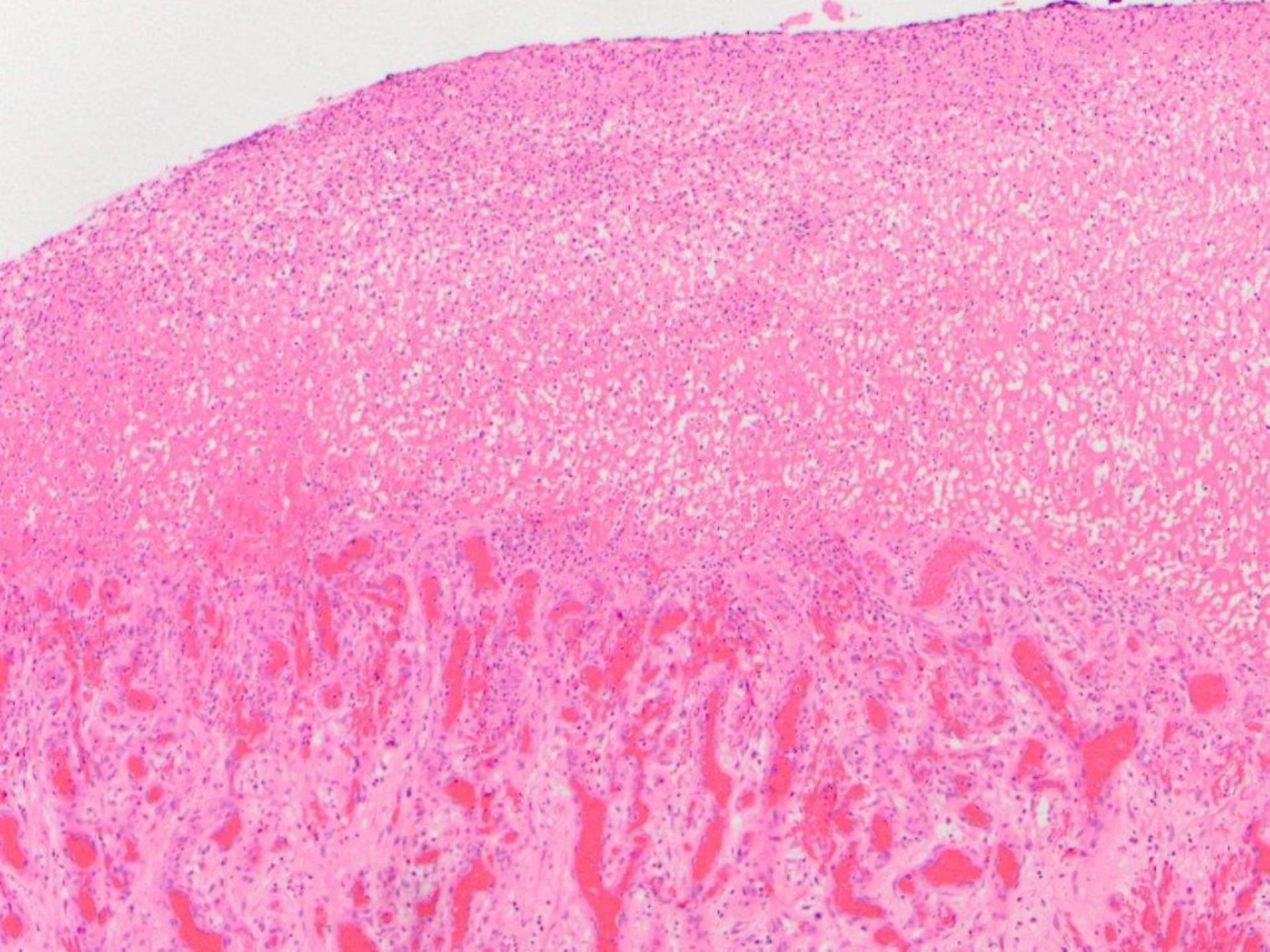


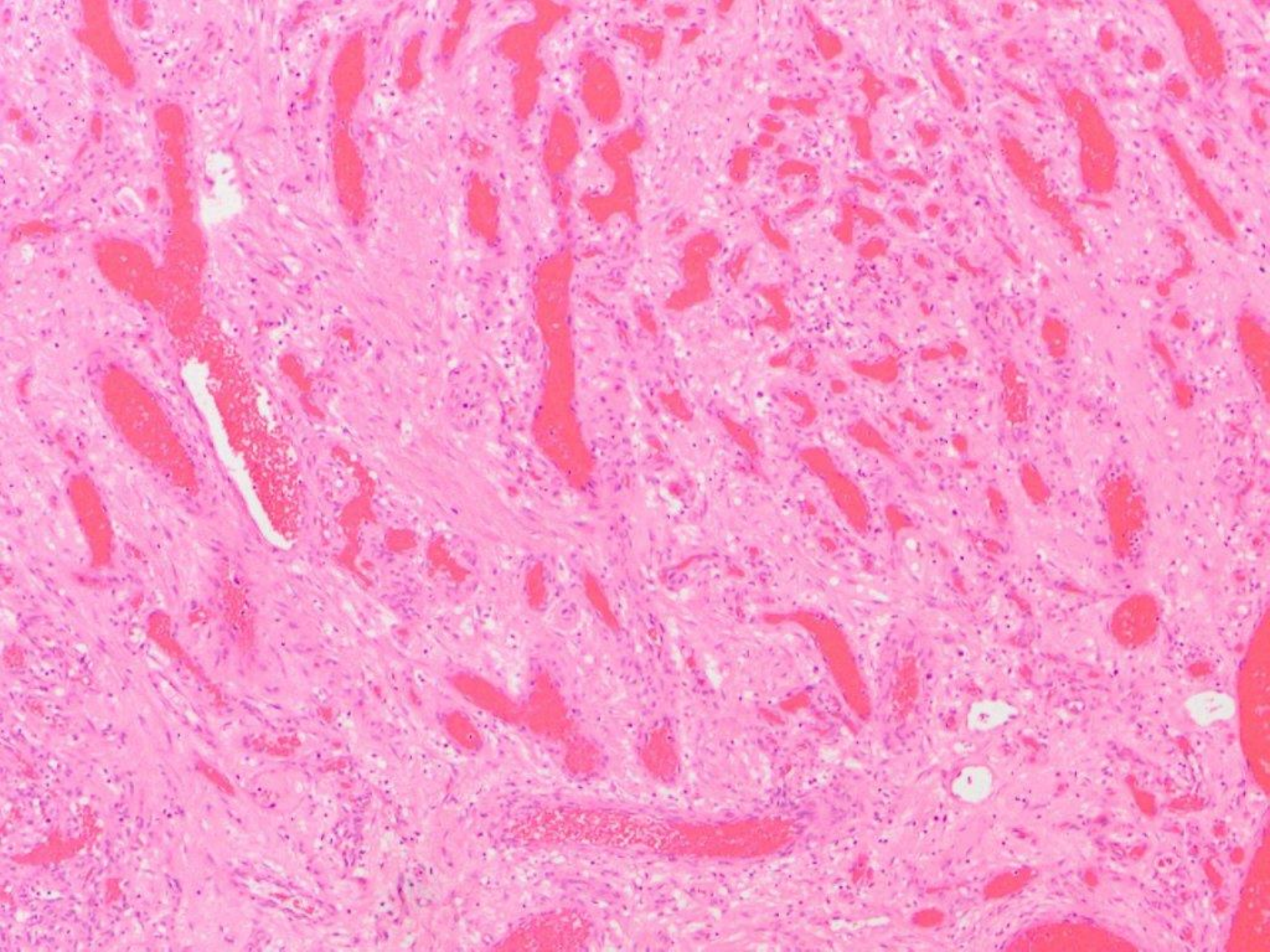


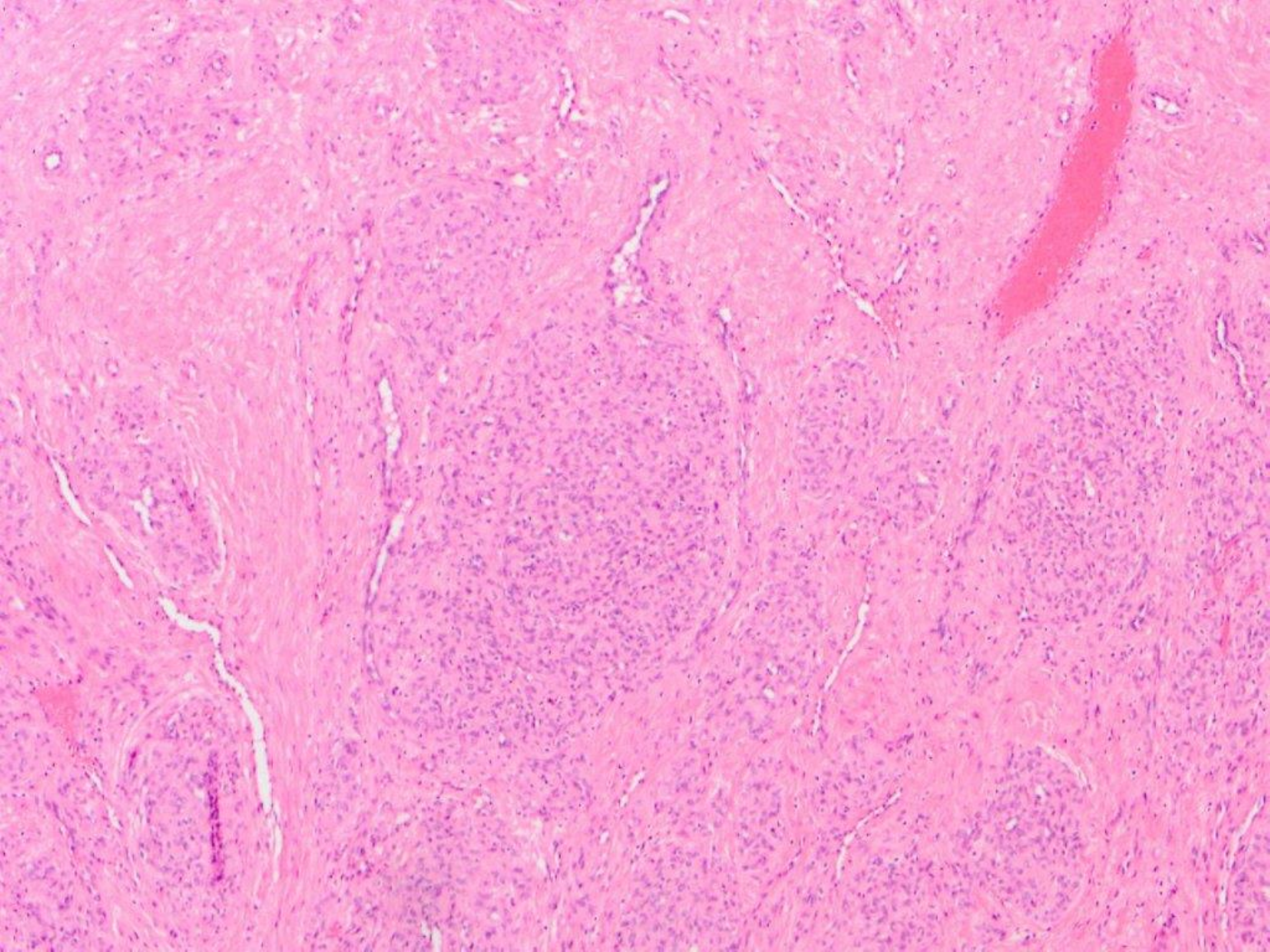


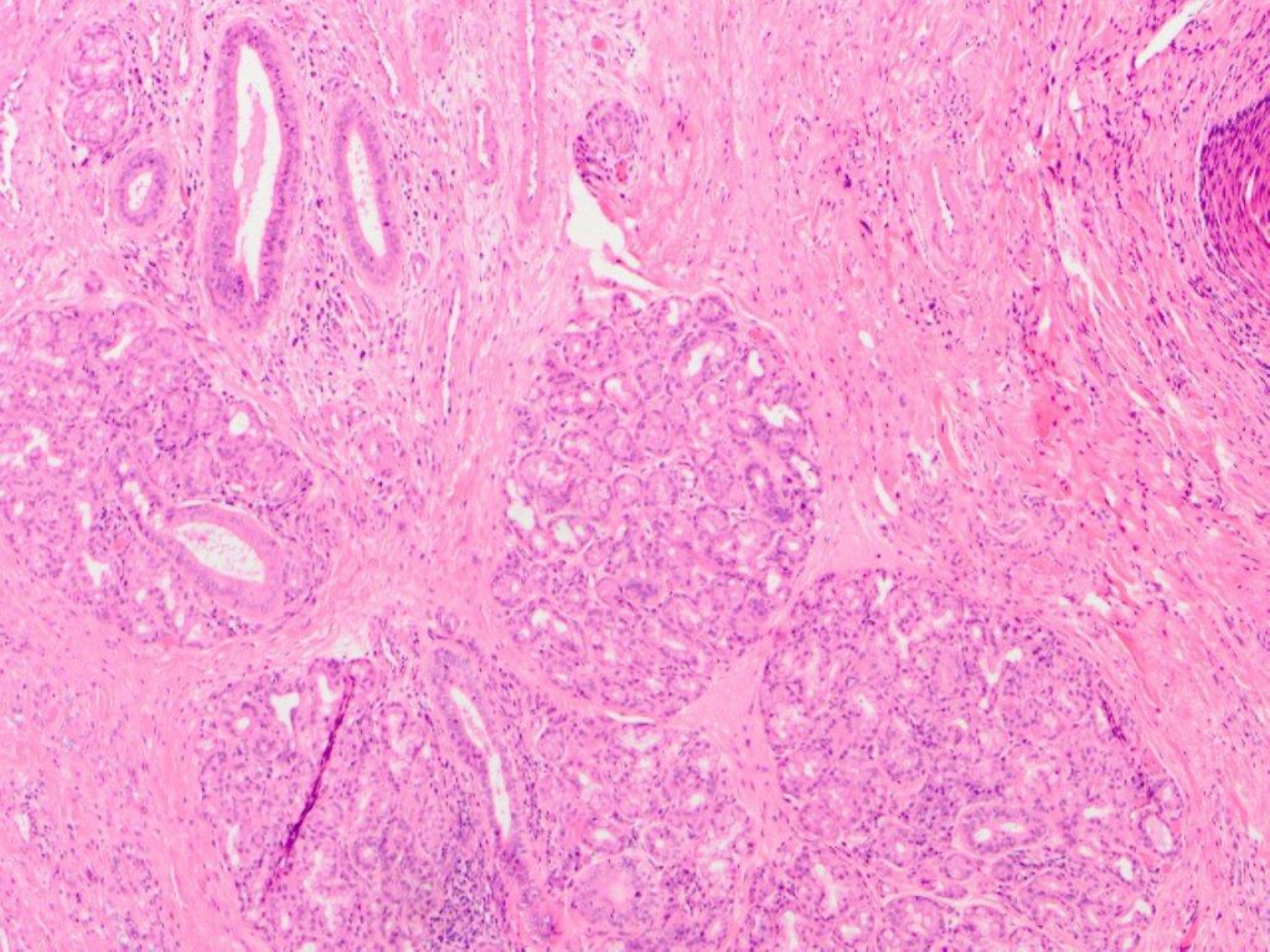
myxoma, cutaneous (superficial angiomyxoma)

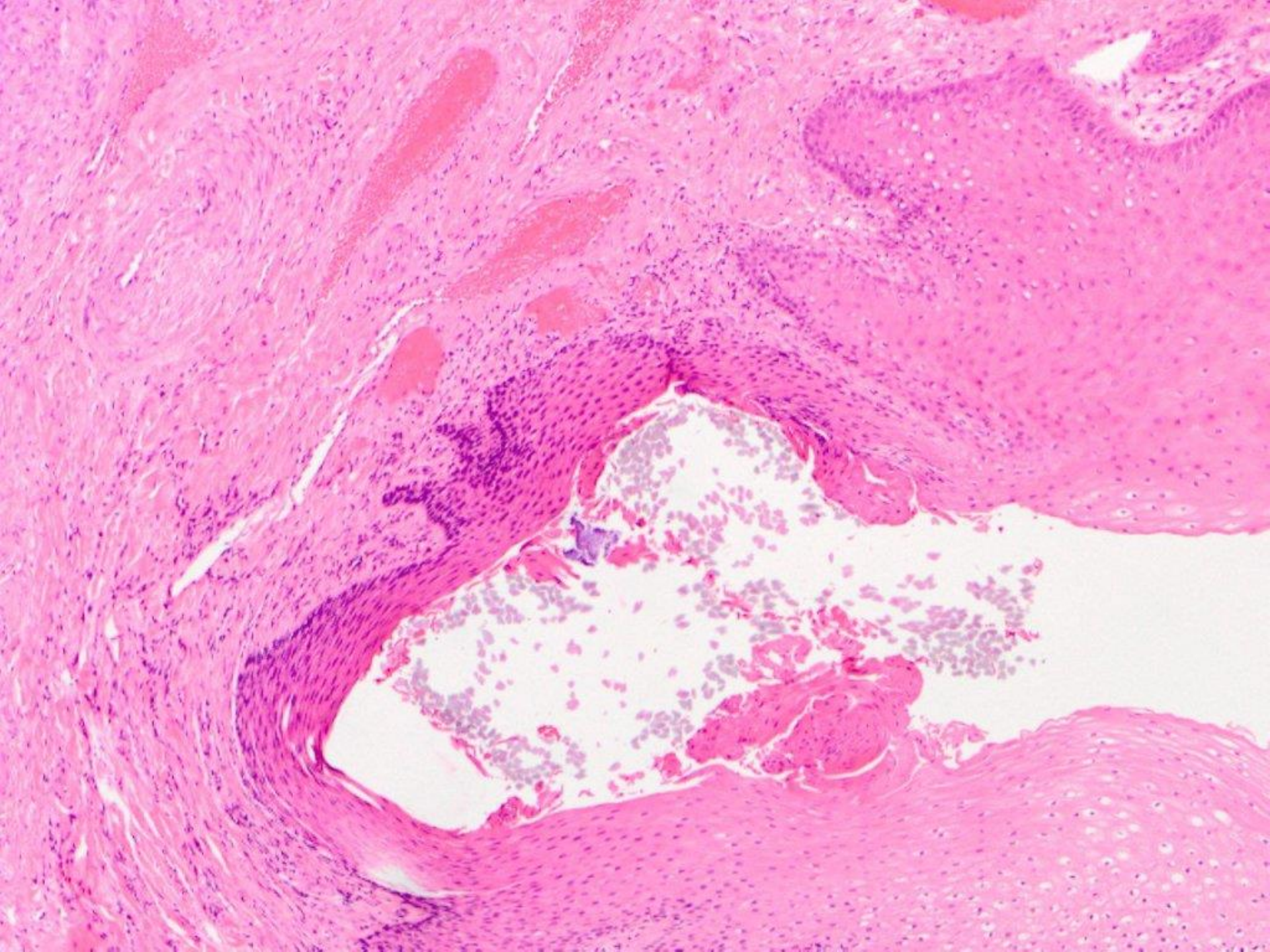


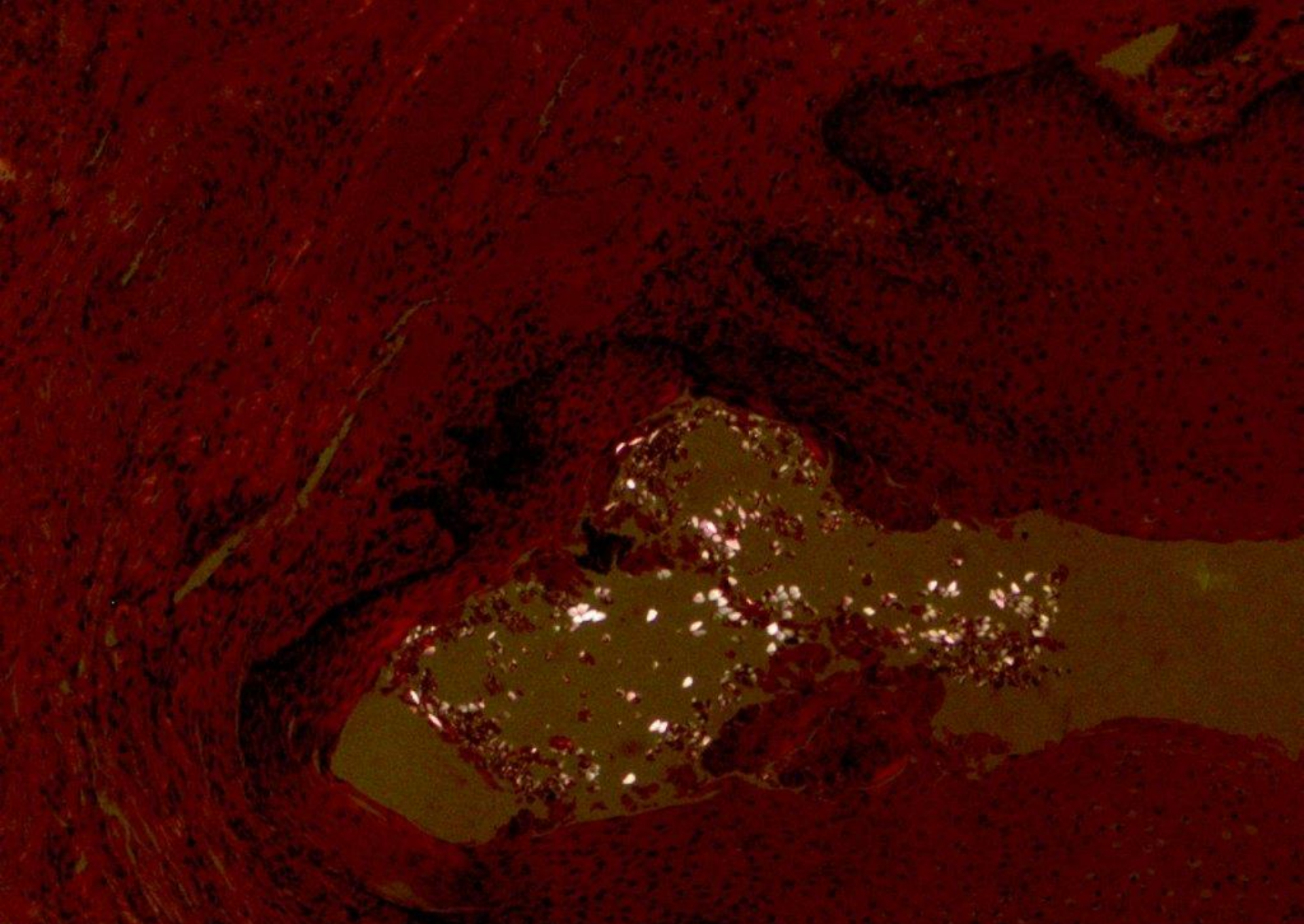






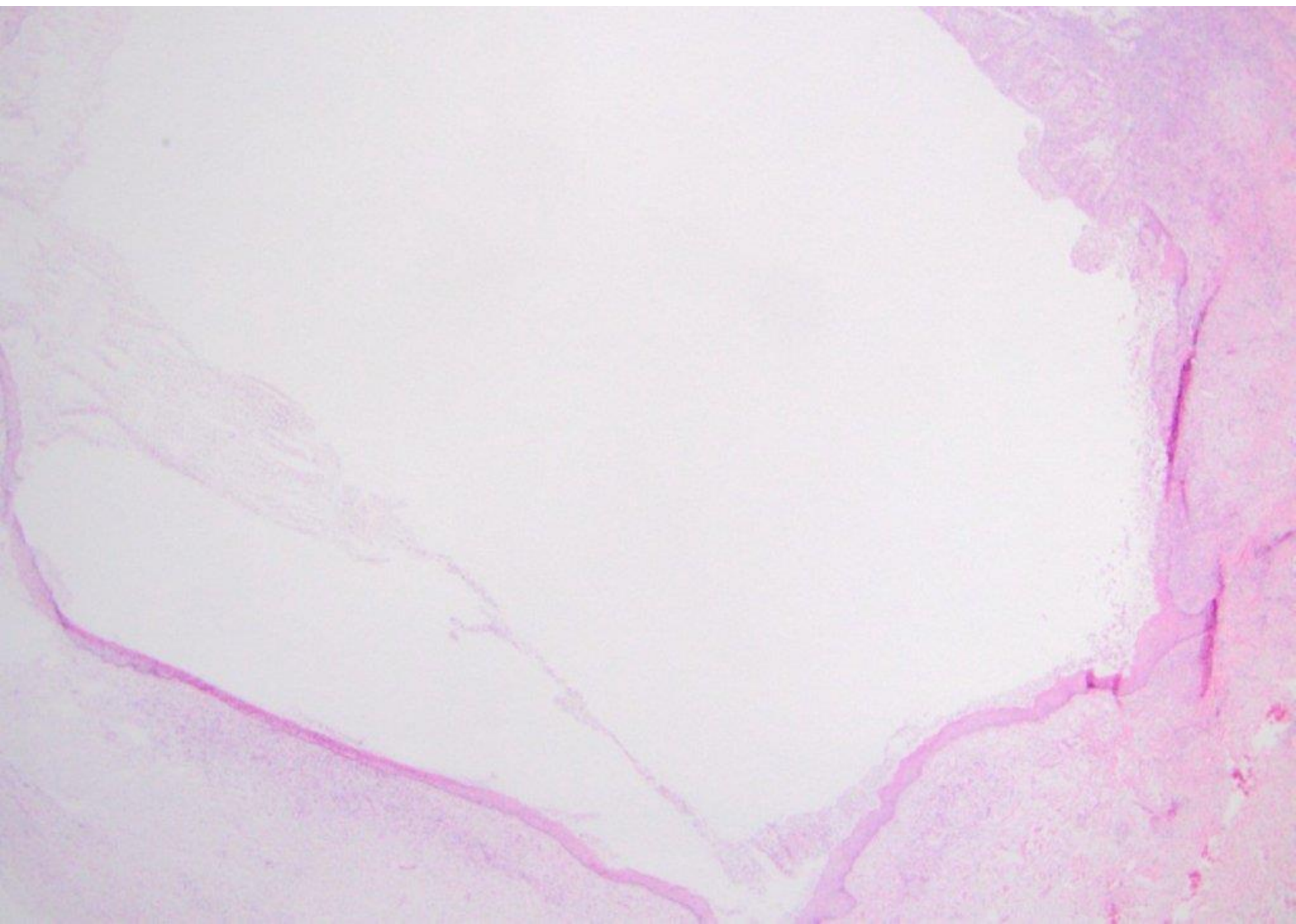


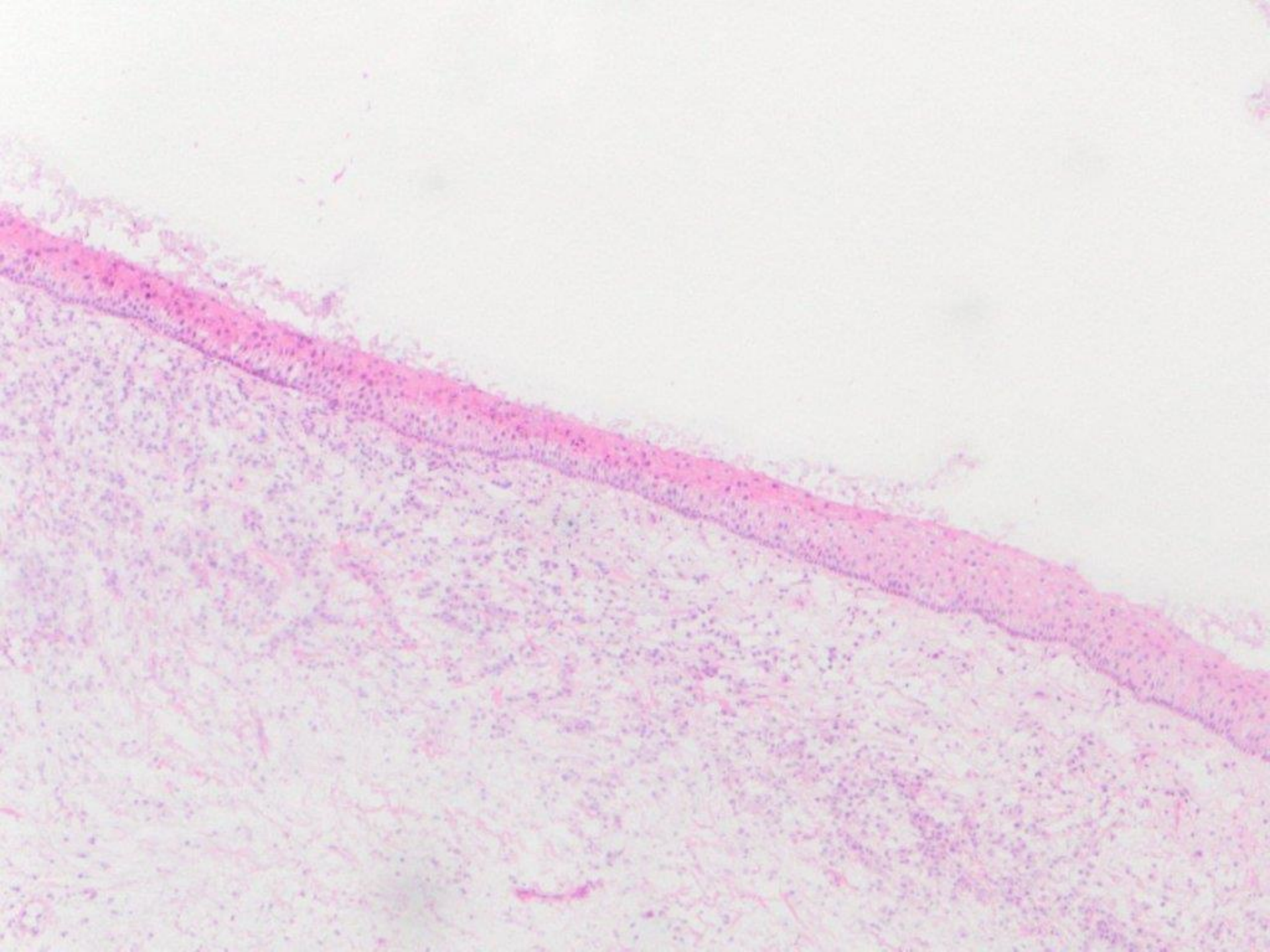


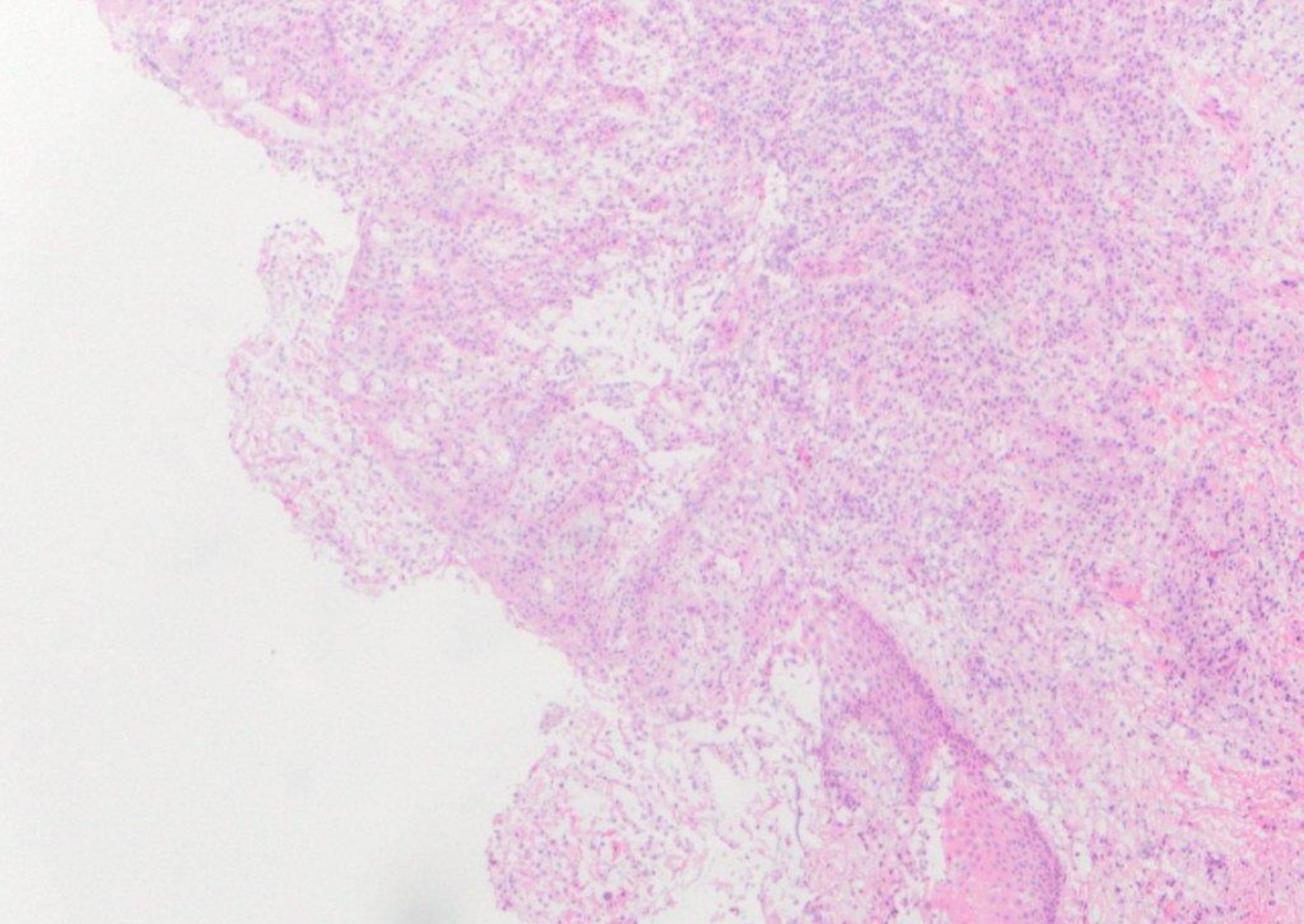


ulcerated lobular capillary hemangioma (sutured at the stalk)

left posterior mandible

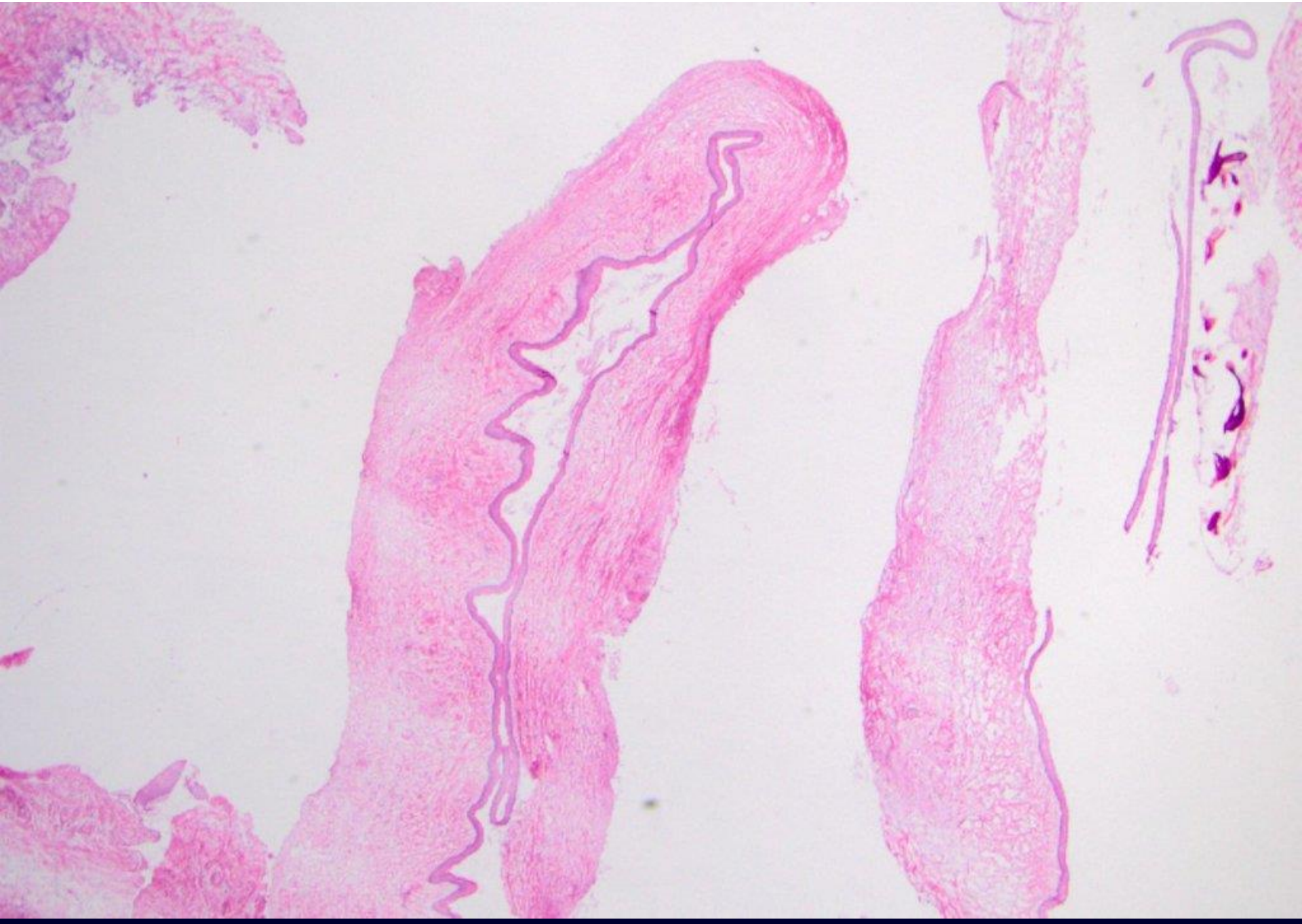


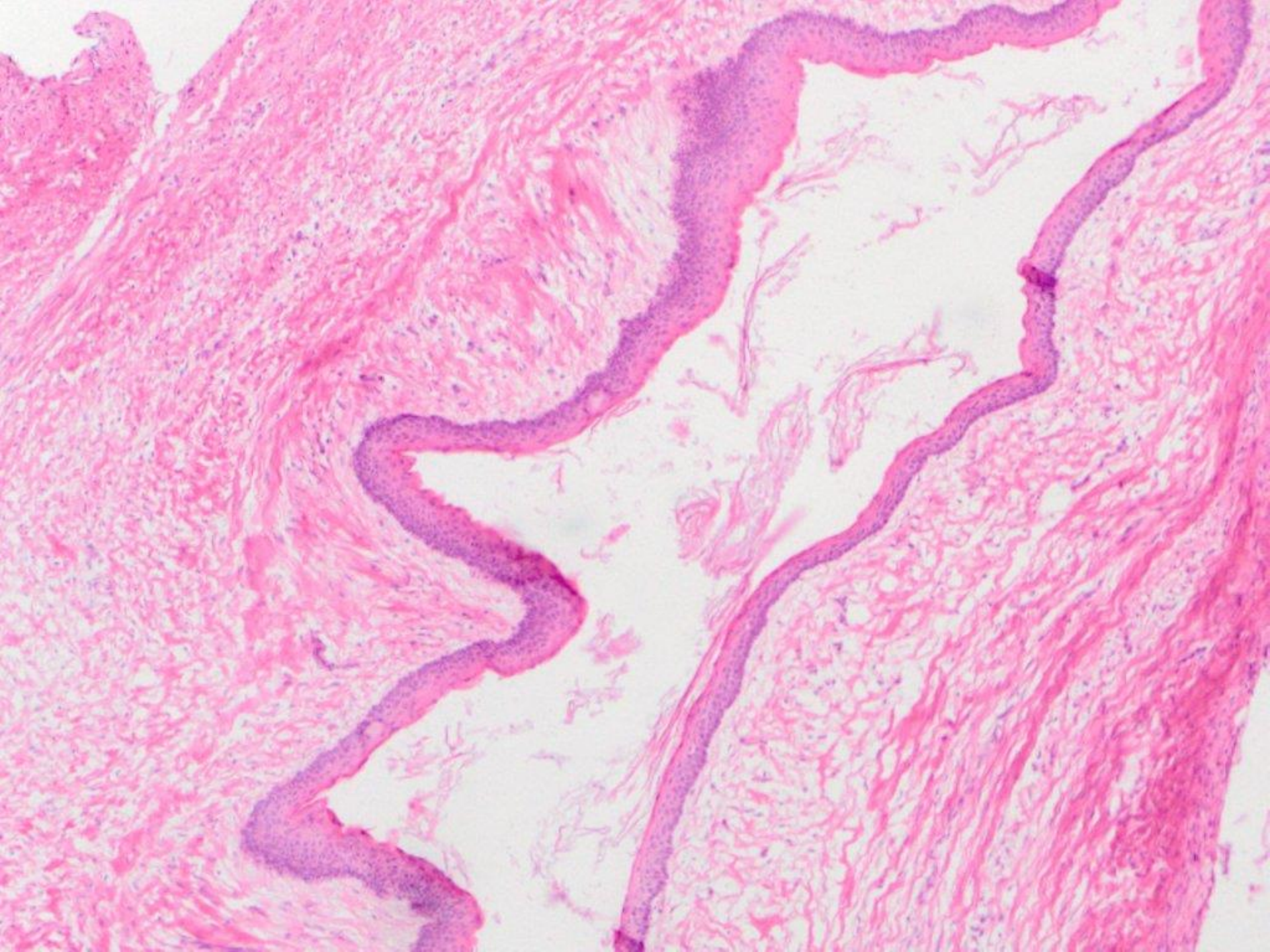


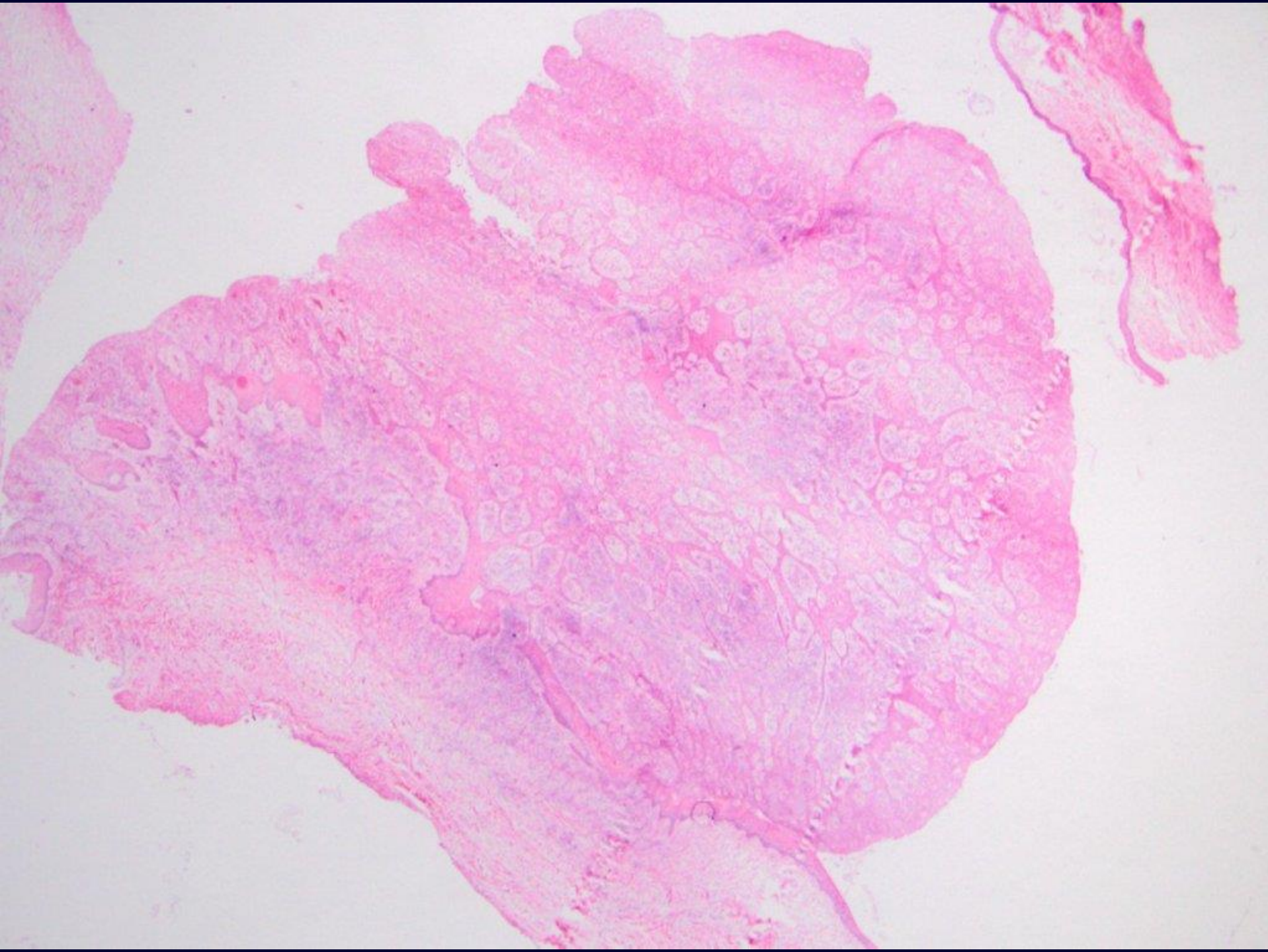


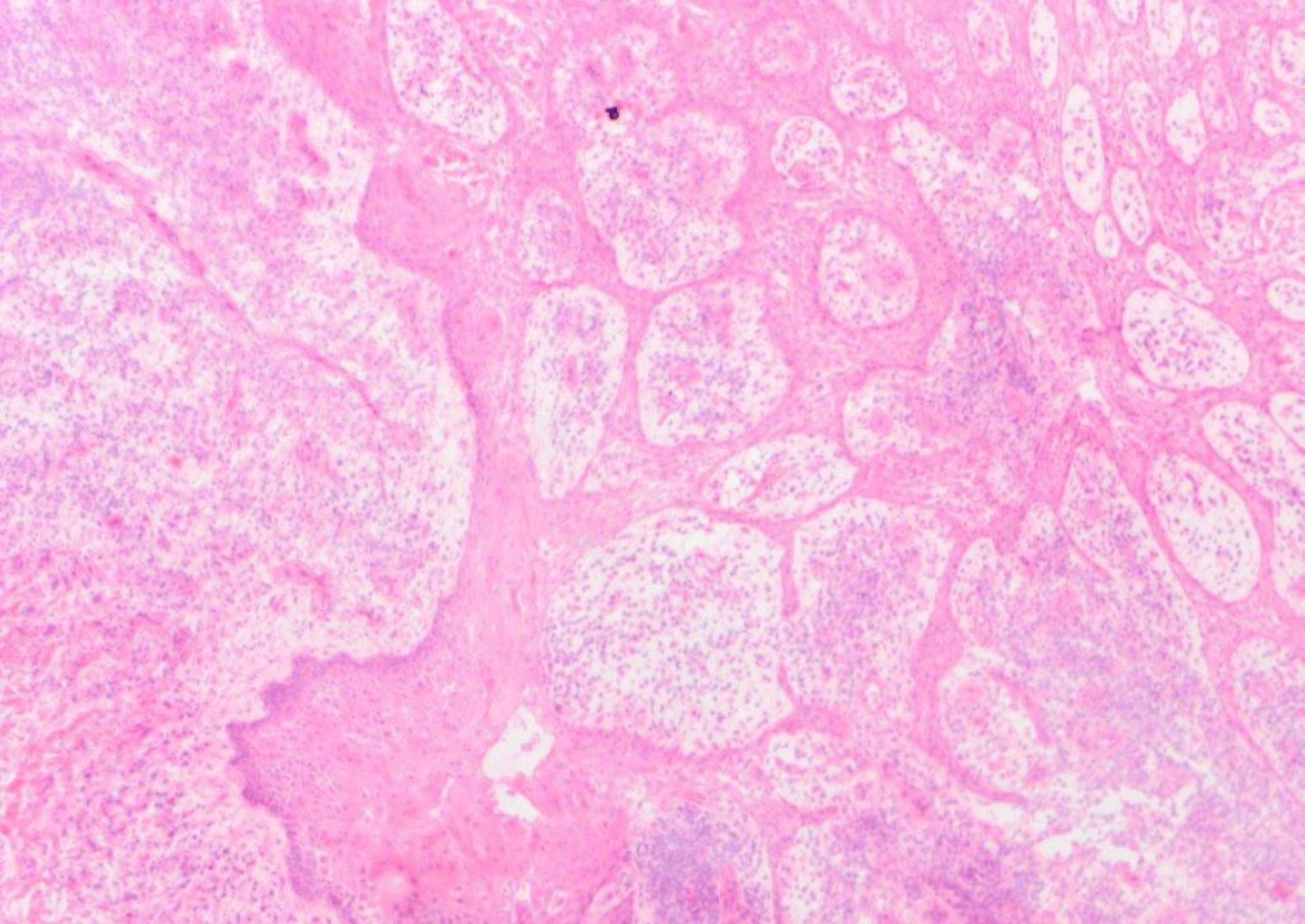
odontogenic keratocyst, inflamed

left posterior maxilla



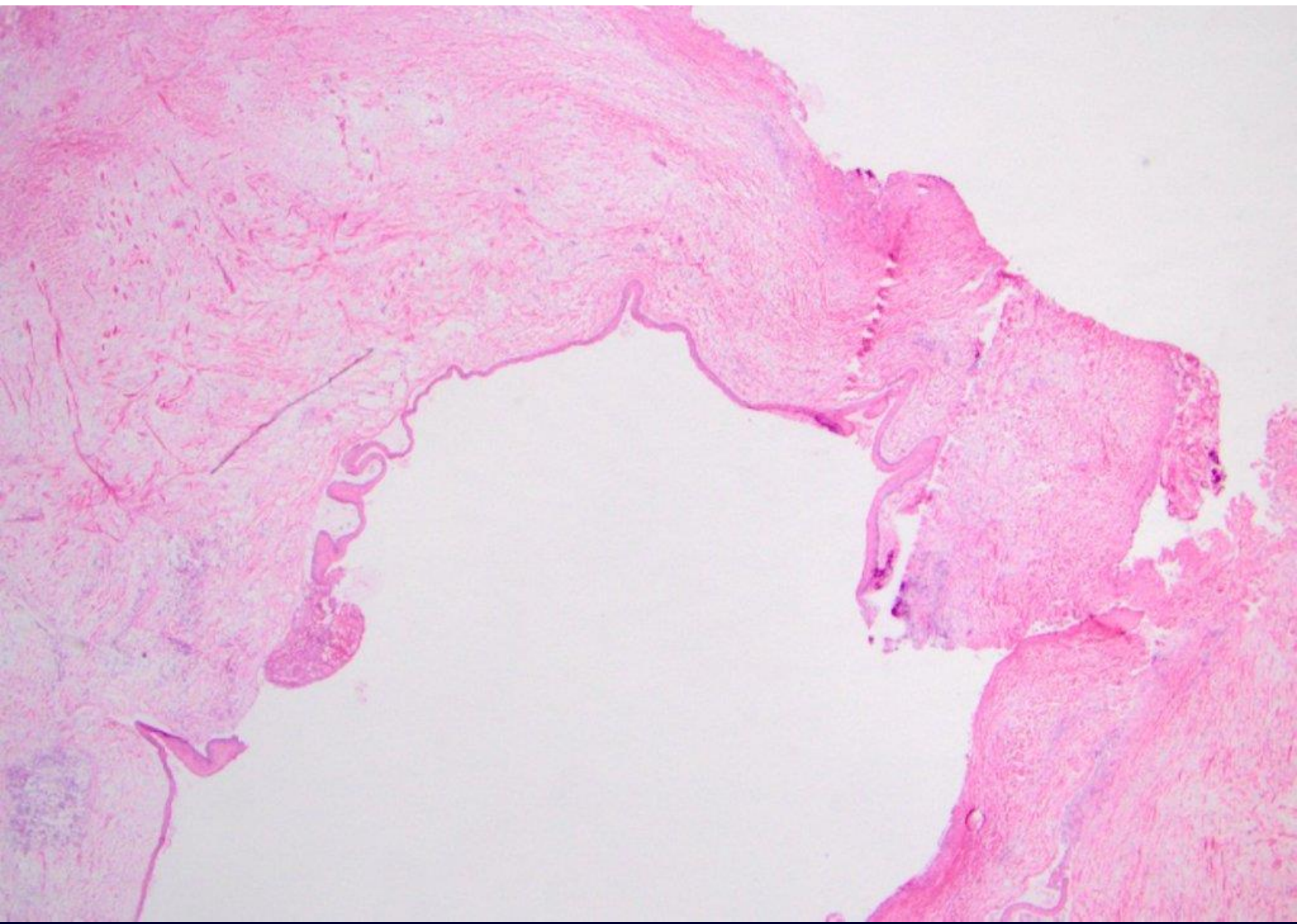


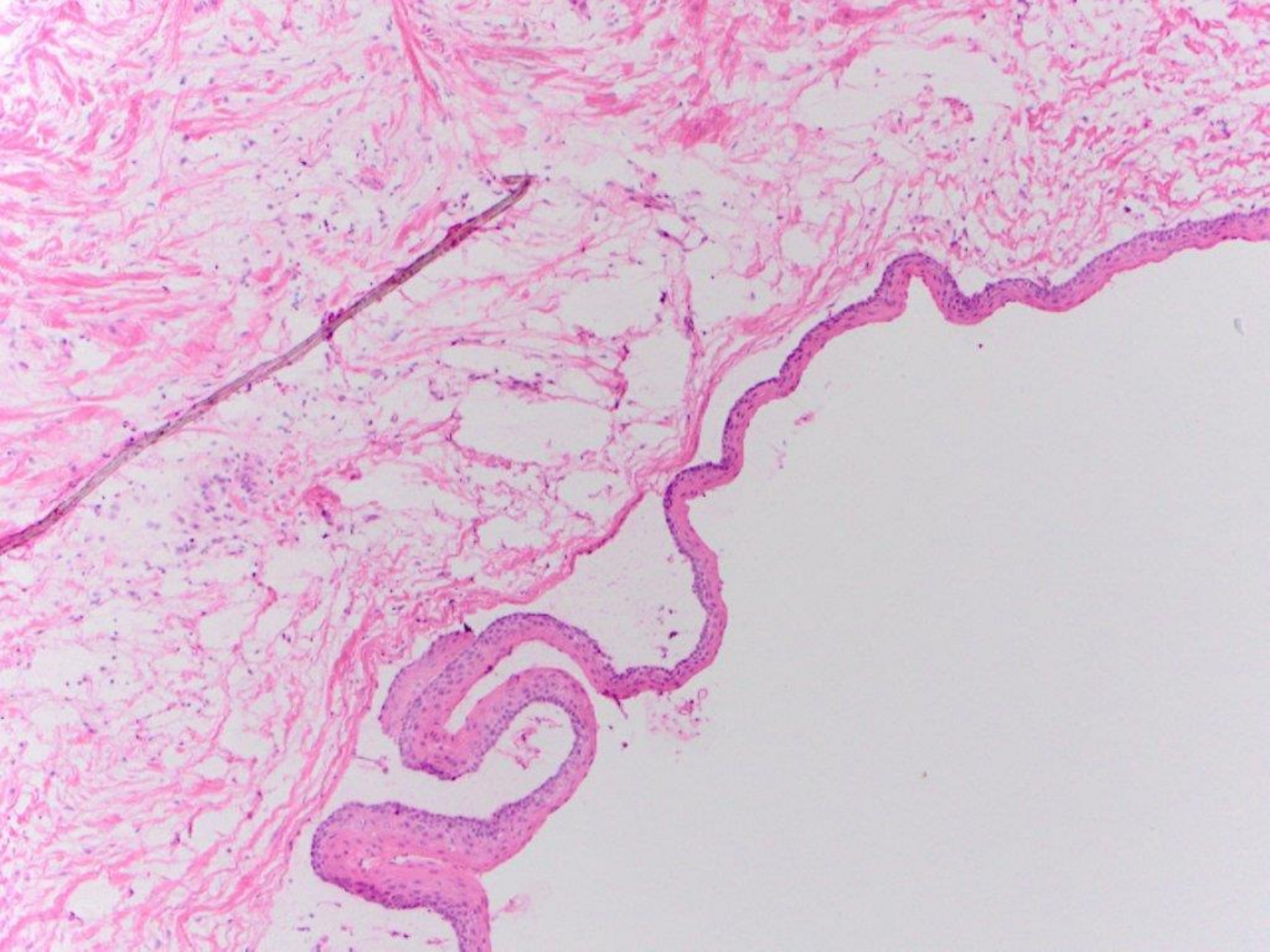


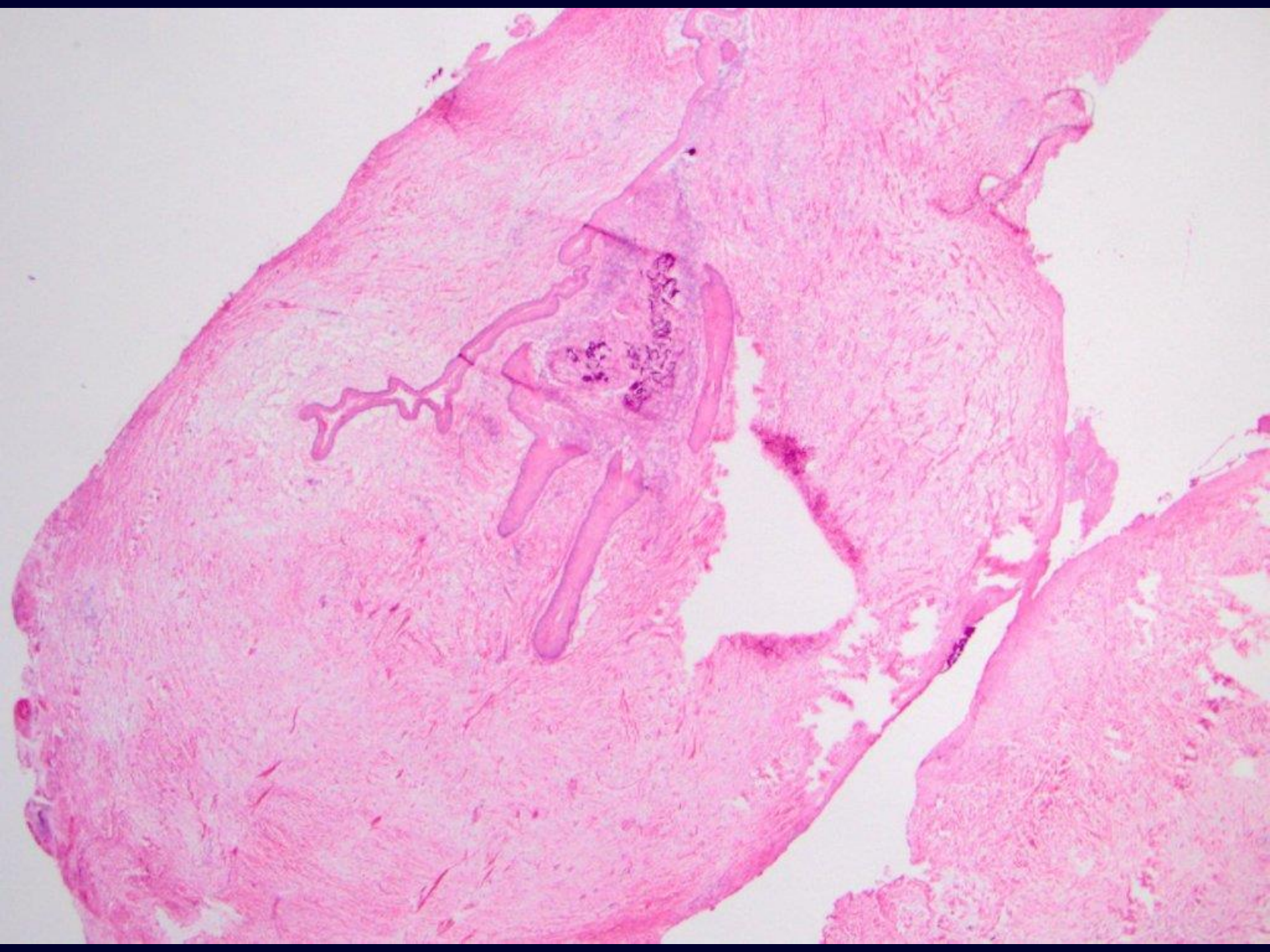


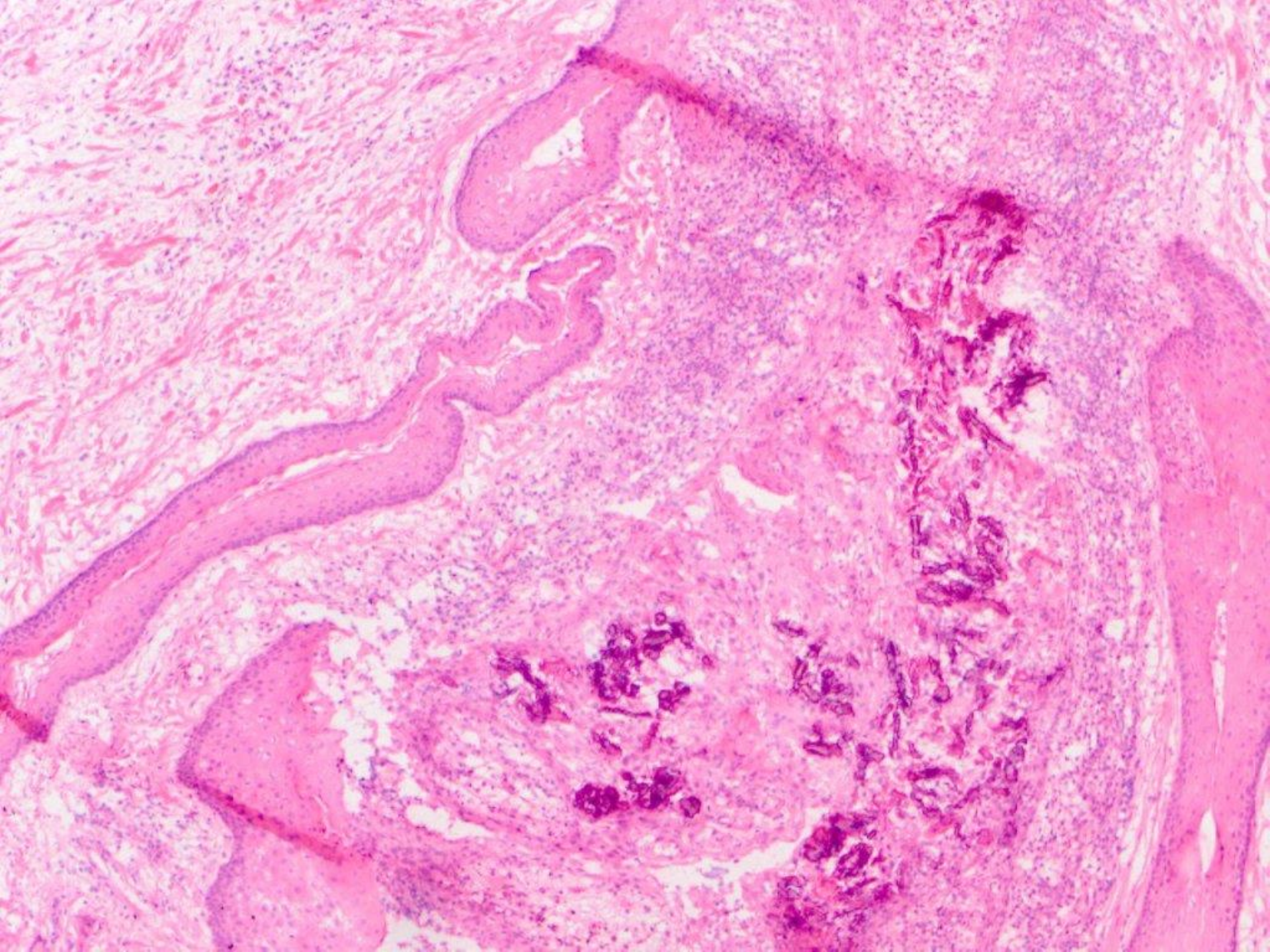
odontogenic keratocyst, proliferative

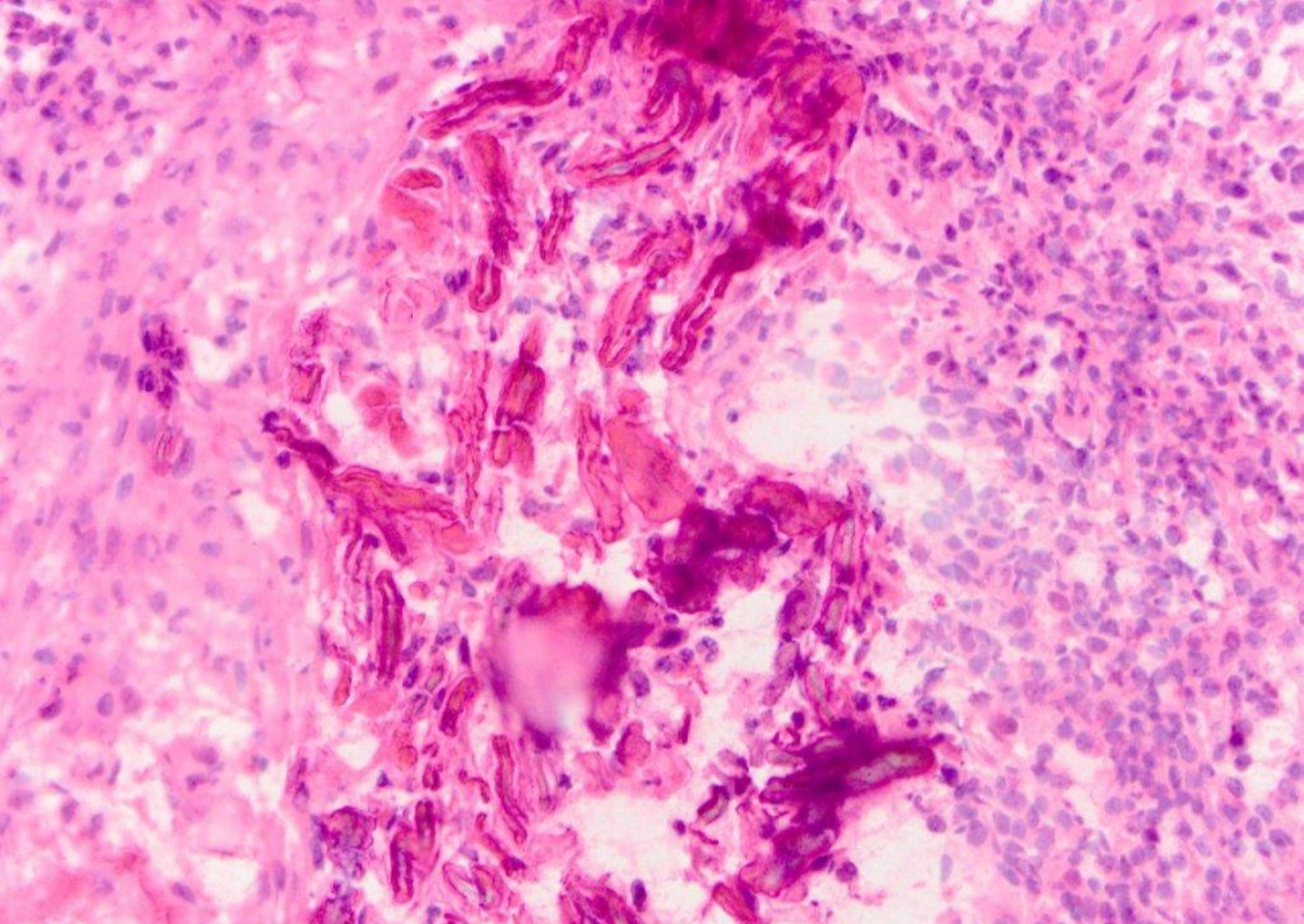
right posterior mandible



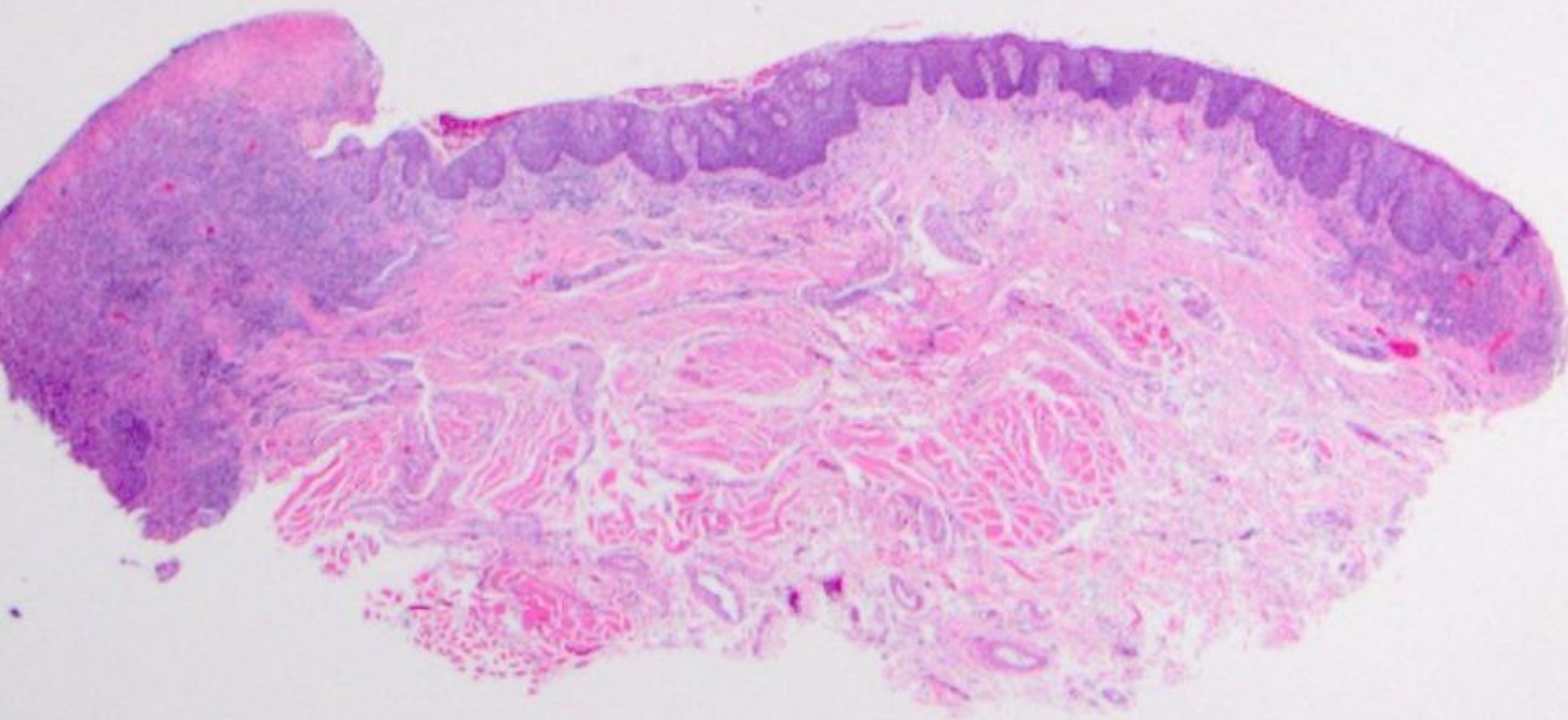


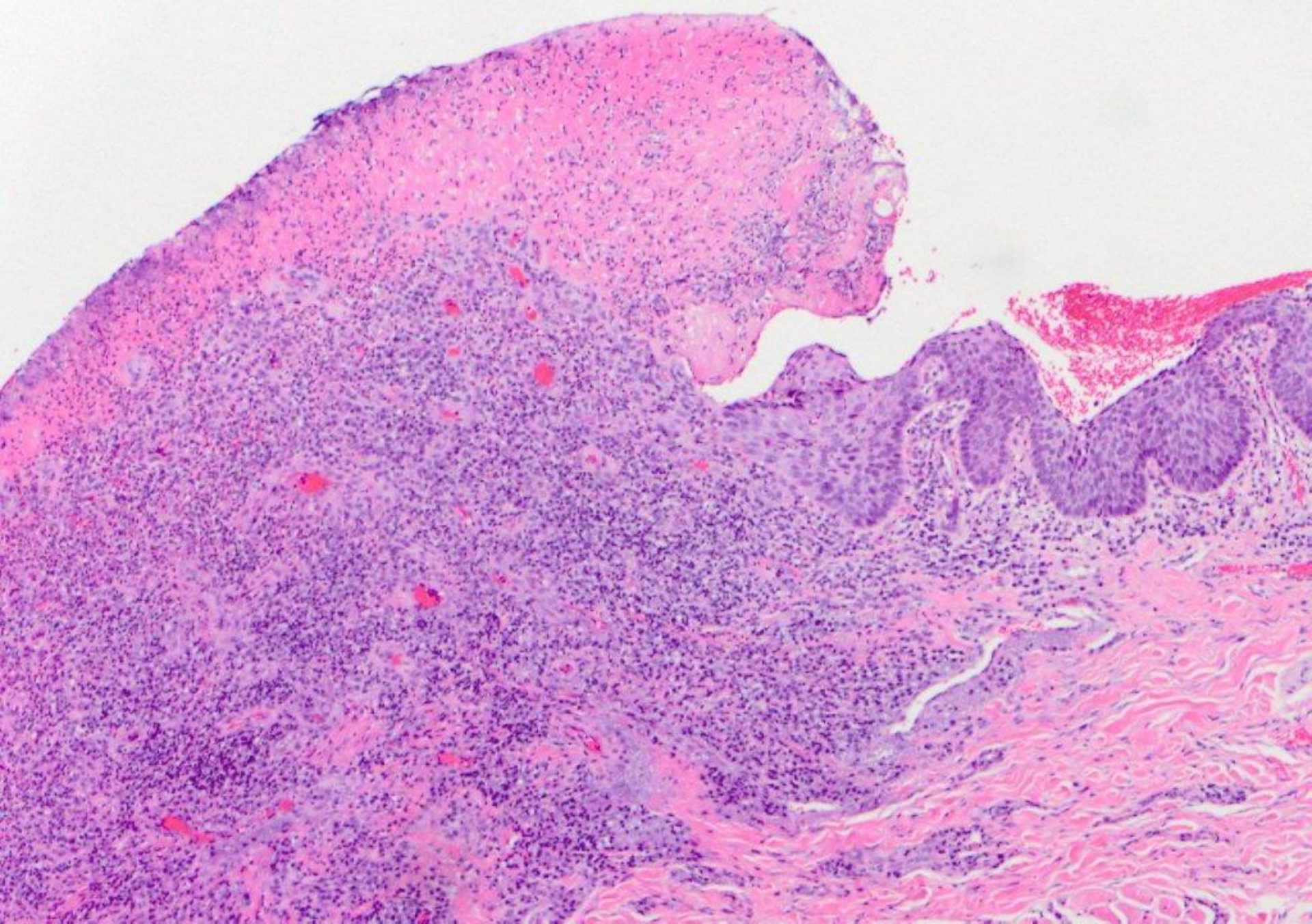


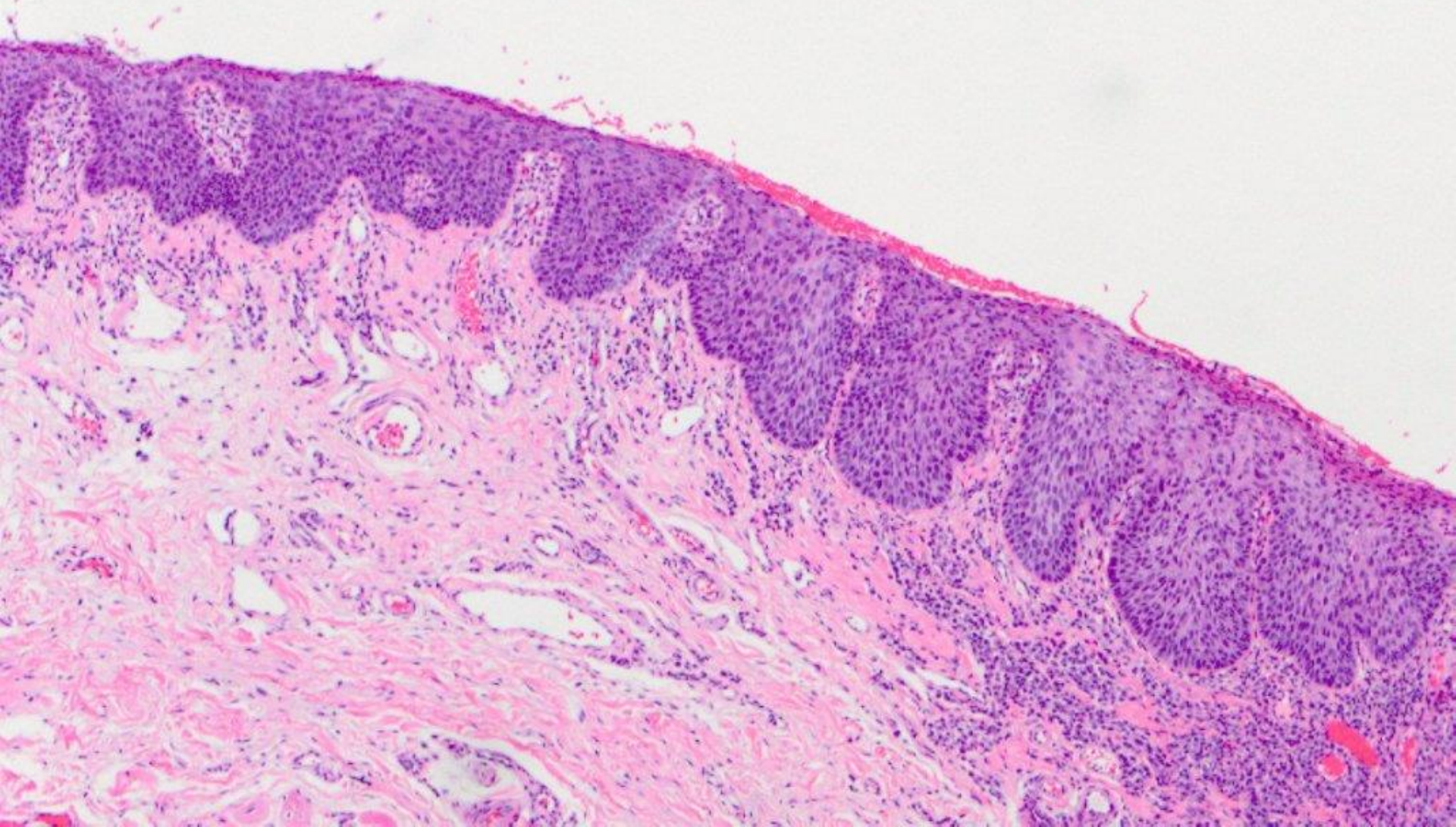


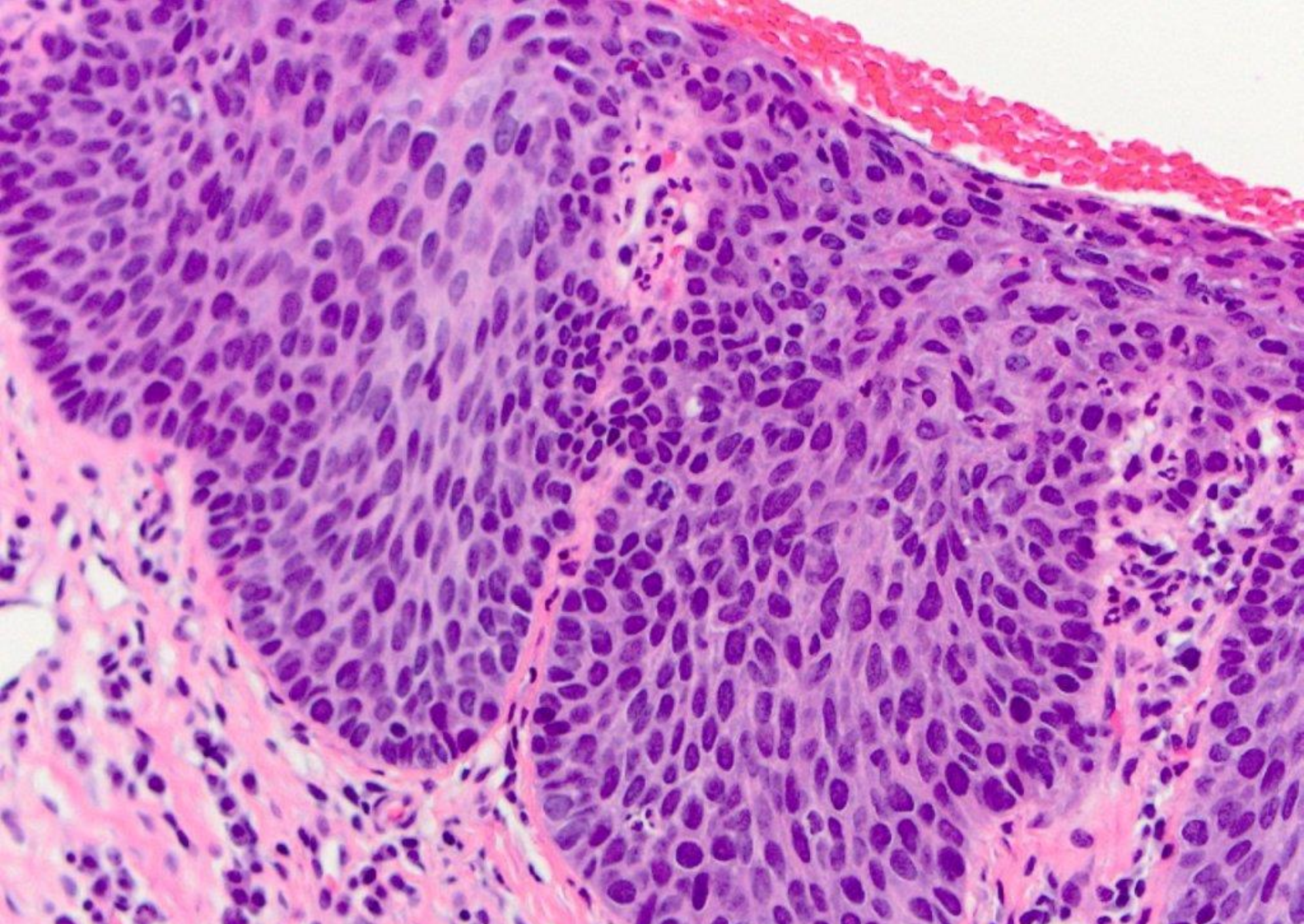


odontogenic keratocyst, with Rushton bodies

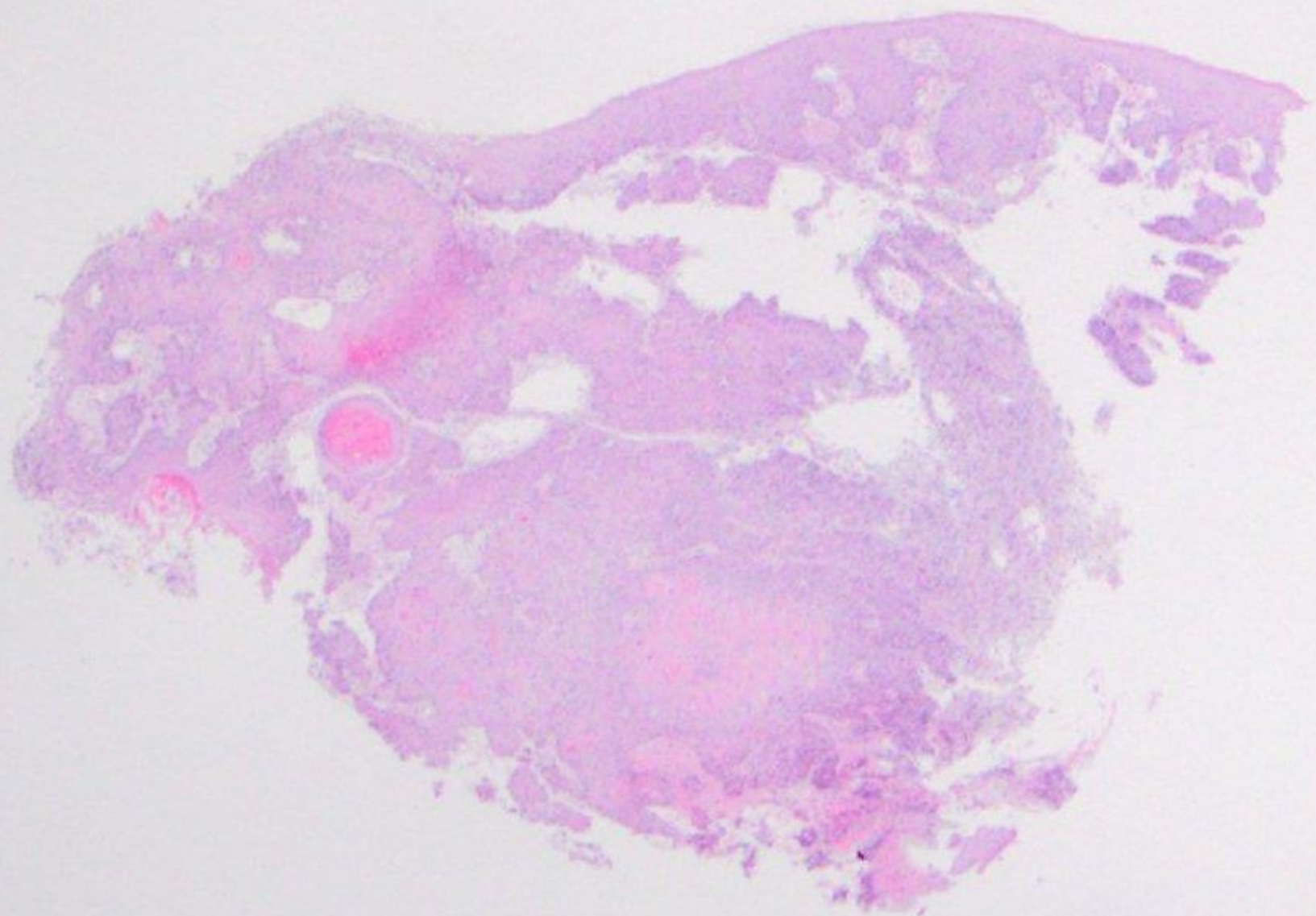


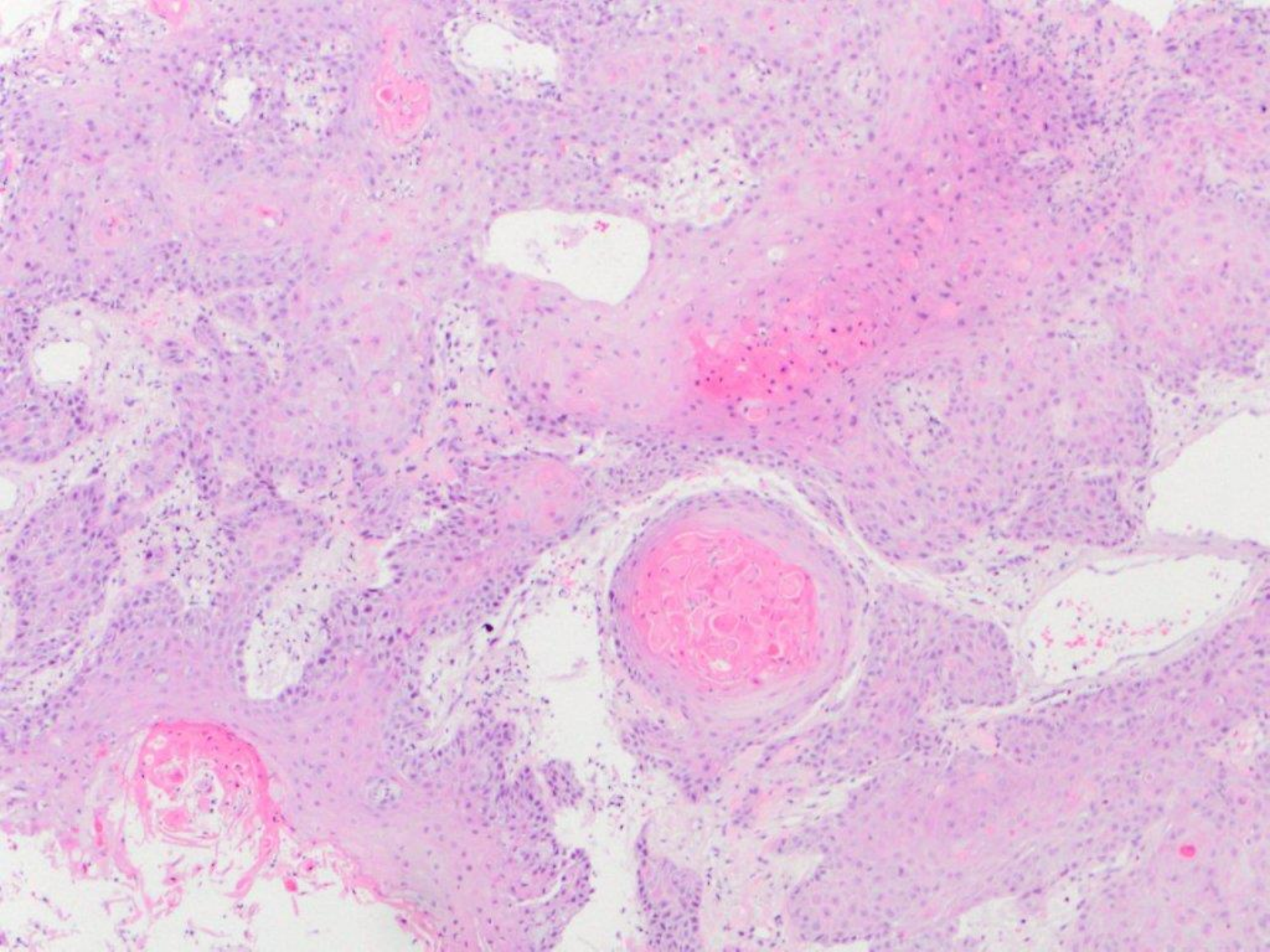


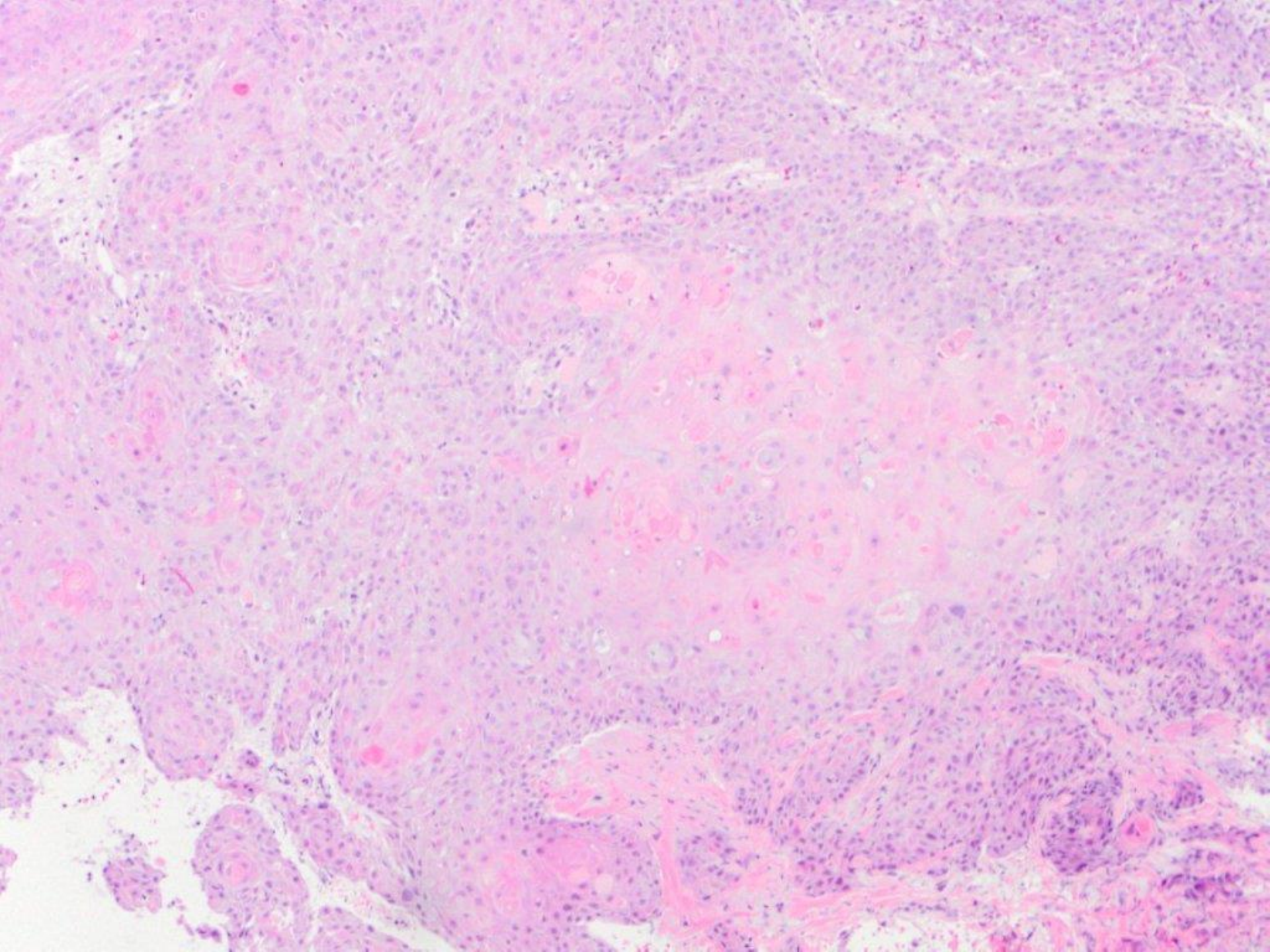


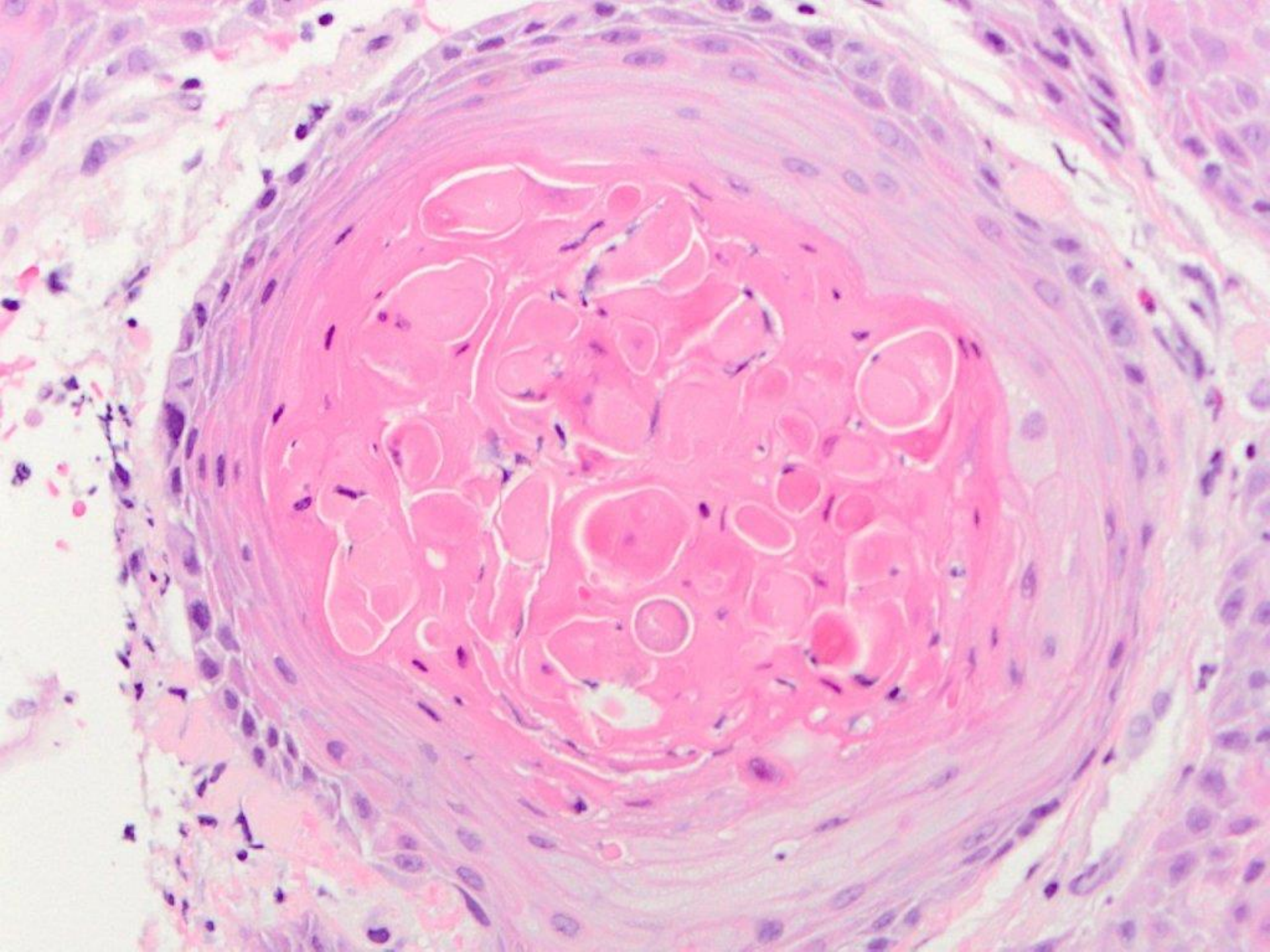


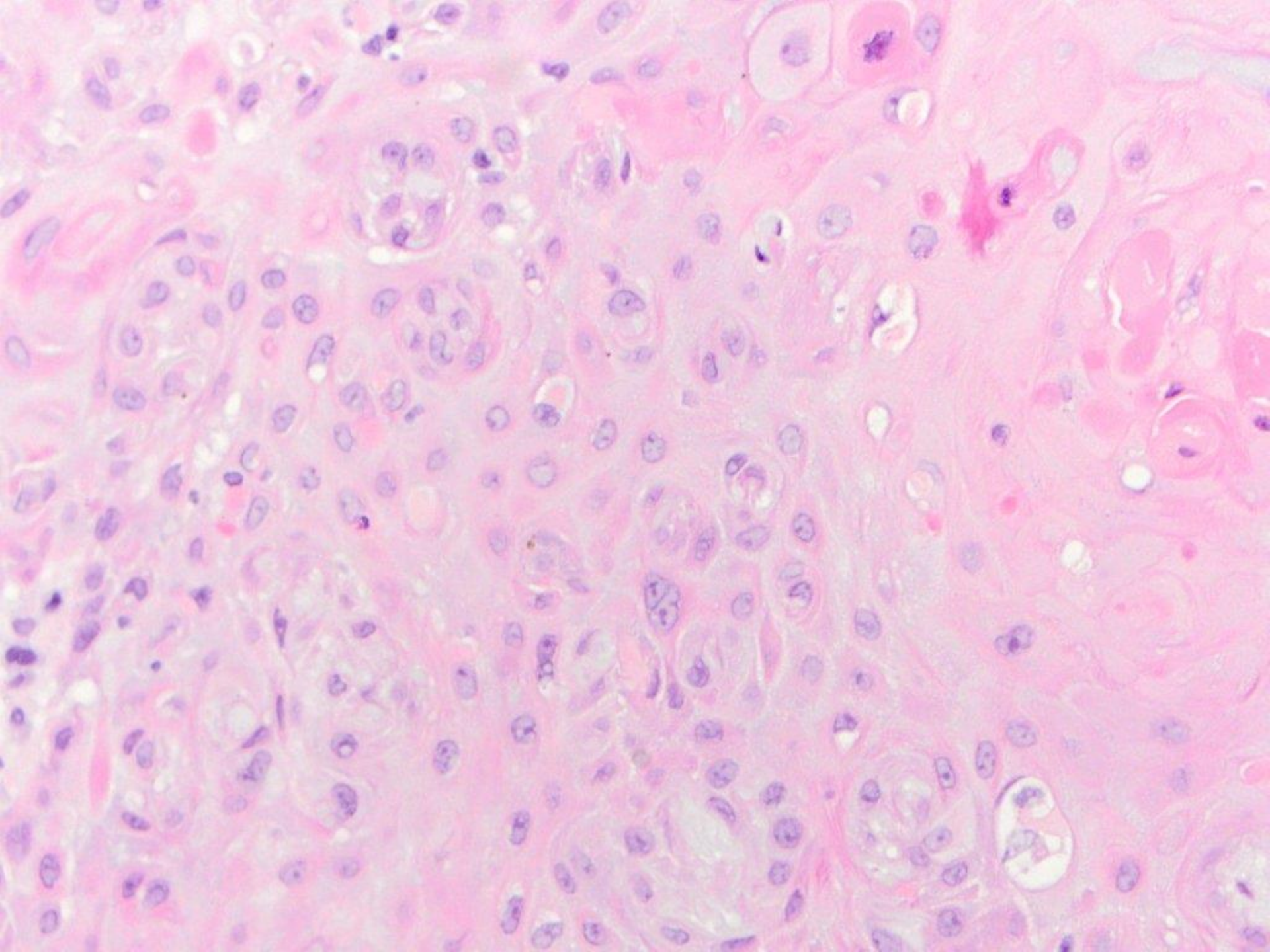
carcinoma in situ

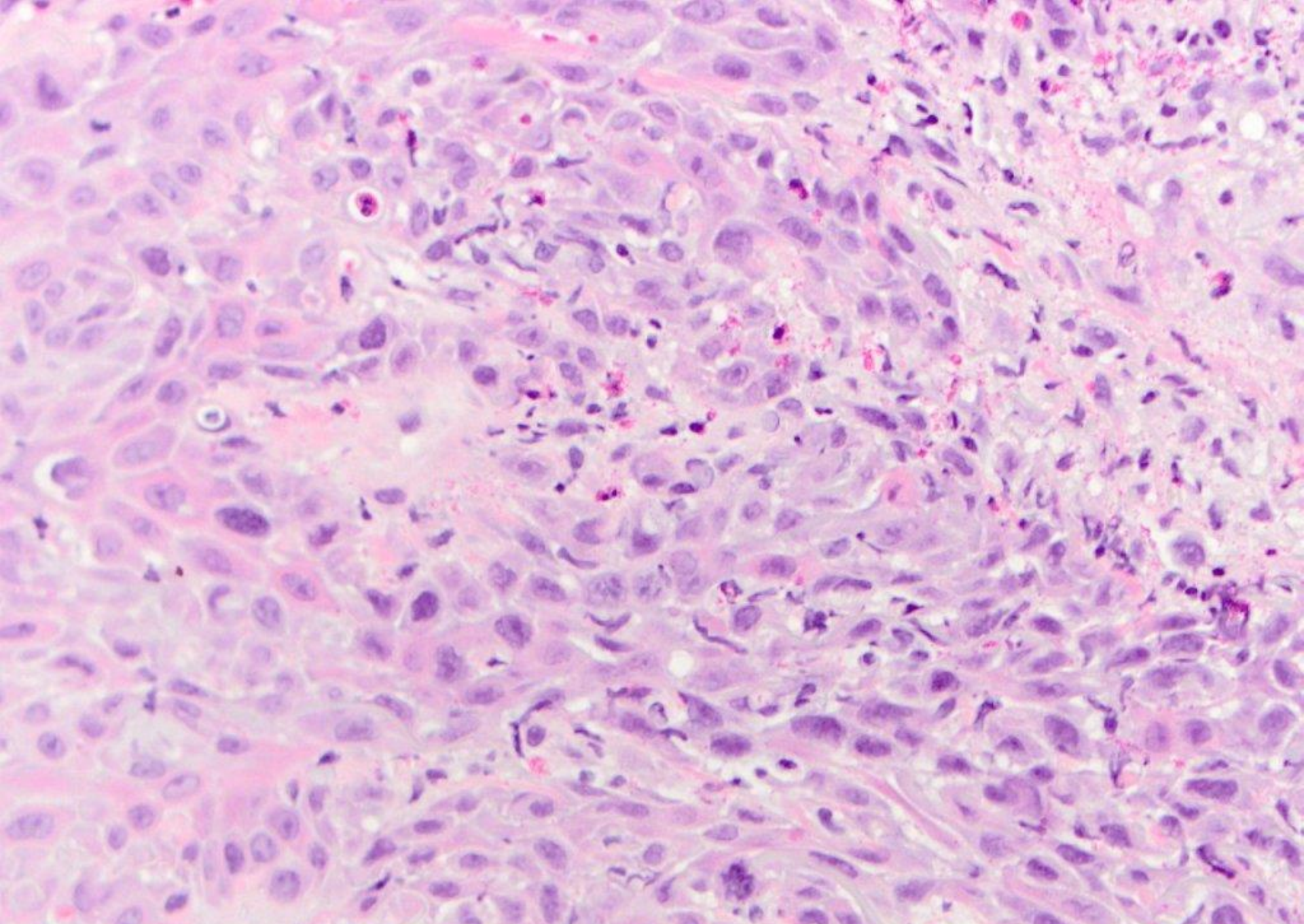




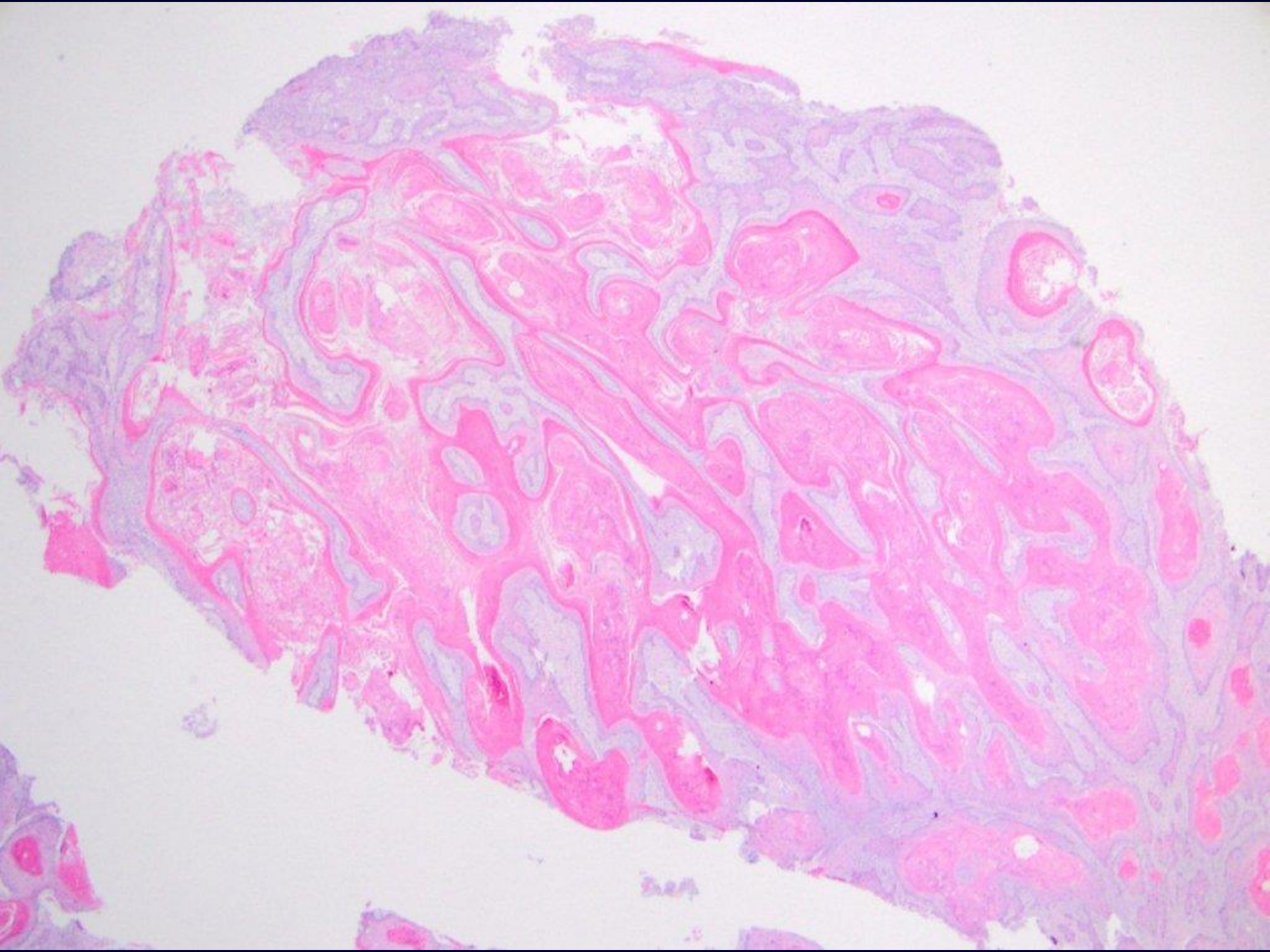


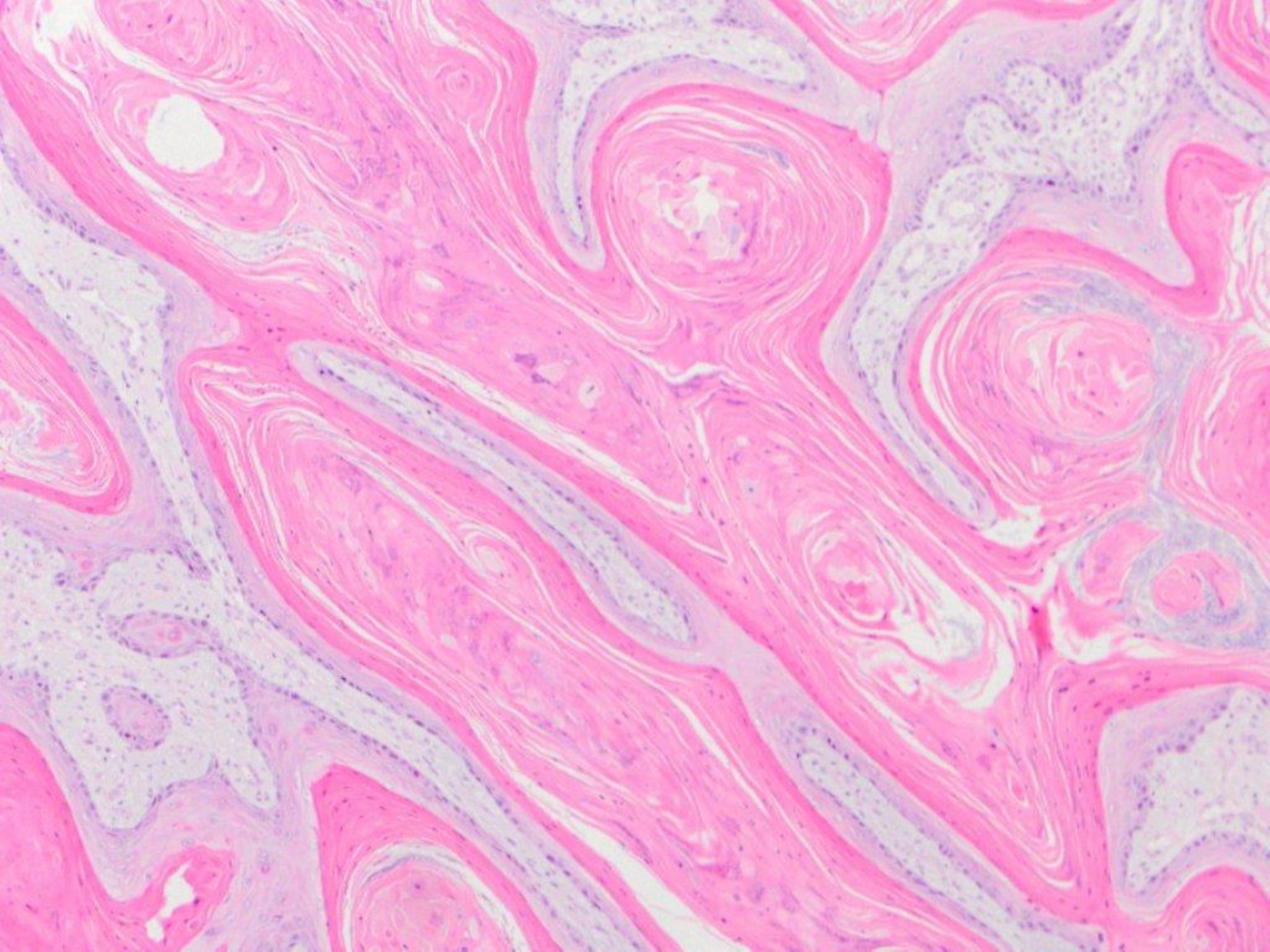


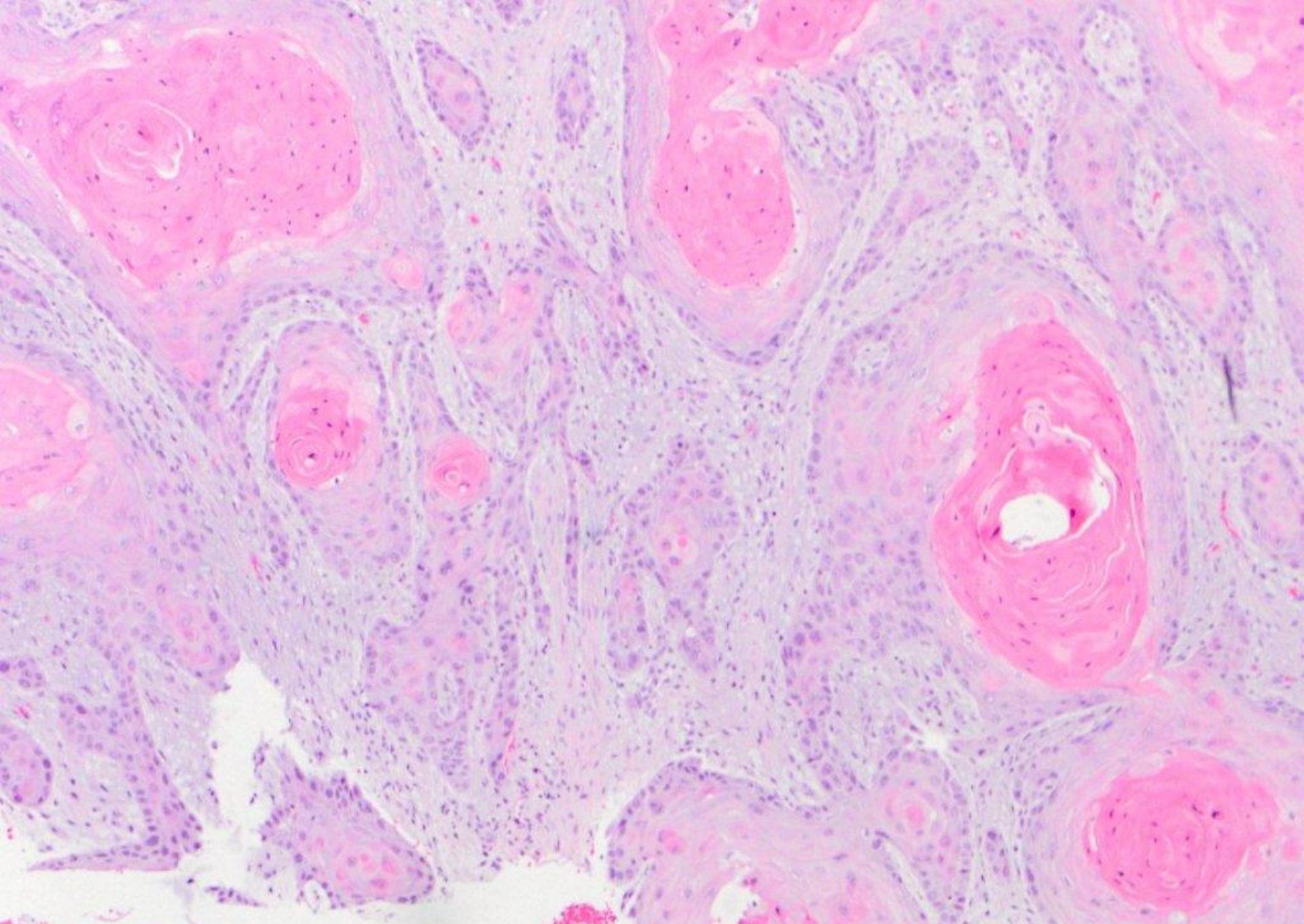




squamous cell carcinoma, well-differentiated (gingiva)

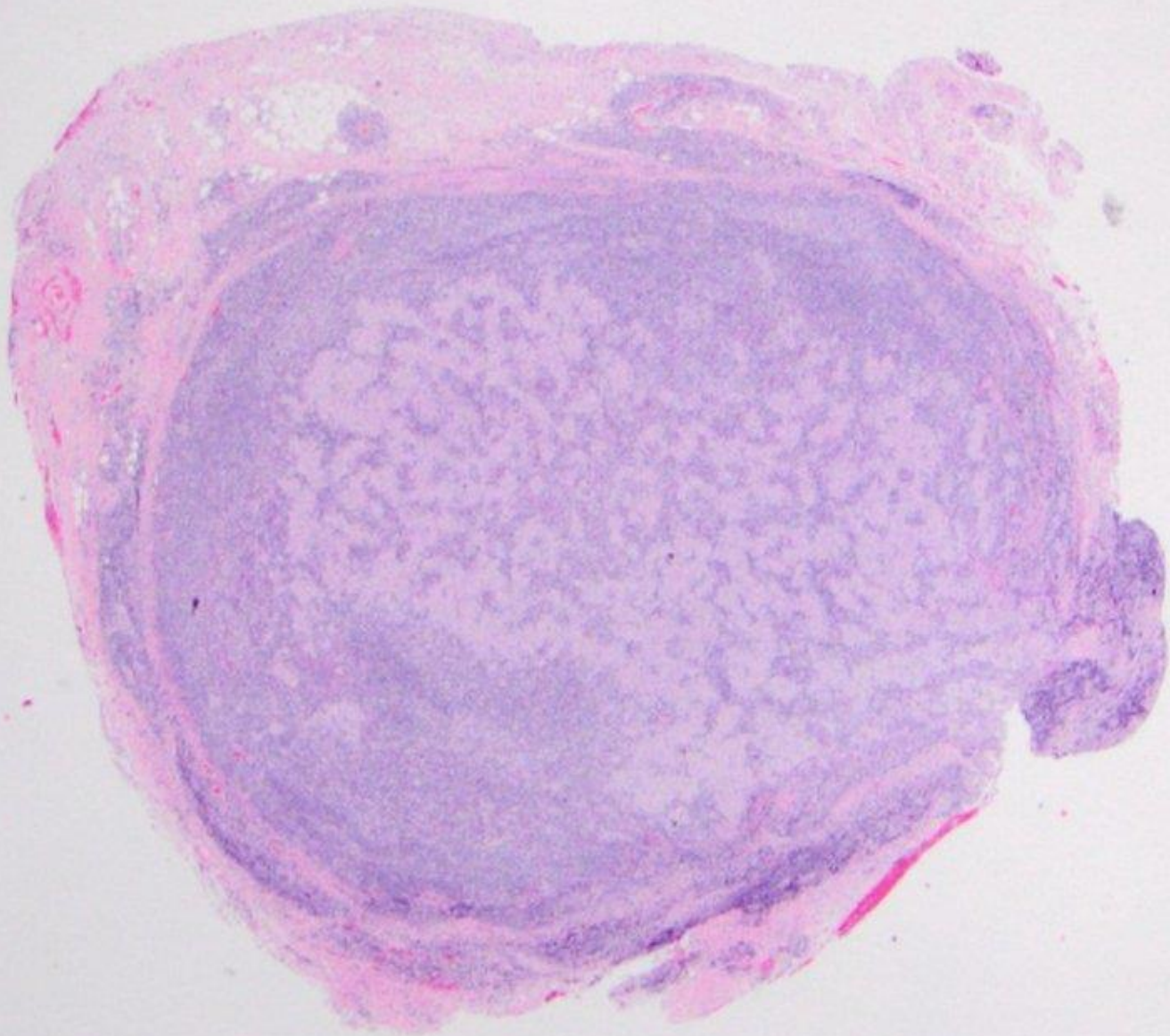




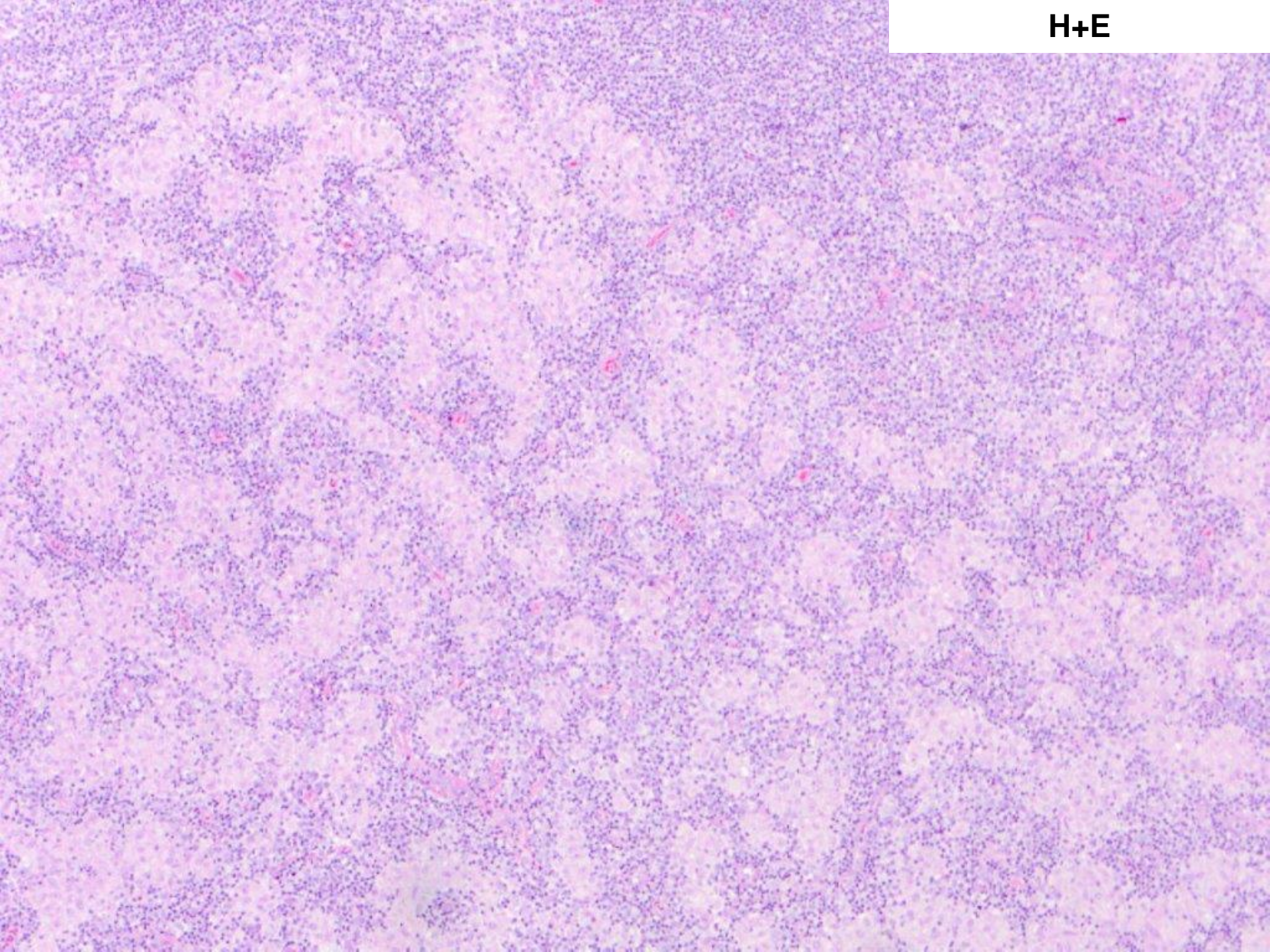


squamous cell carcinoma, well-differentiated (tongue)

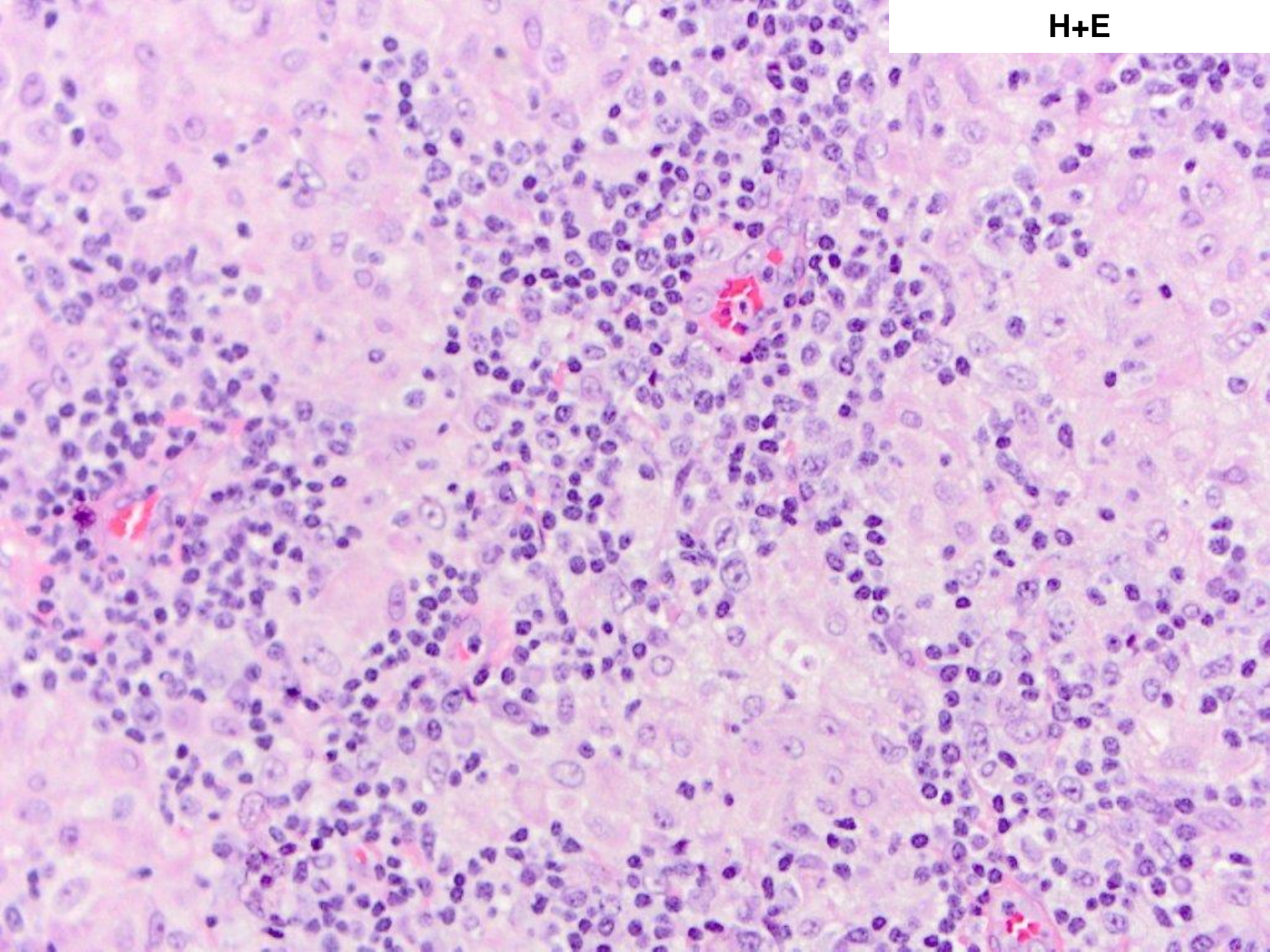
buccal mucosa/vestibule



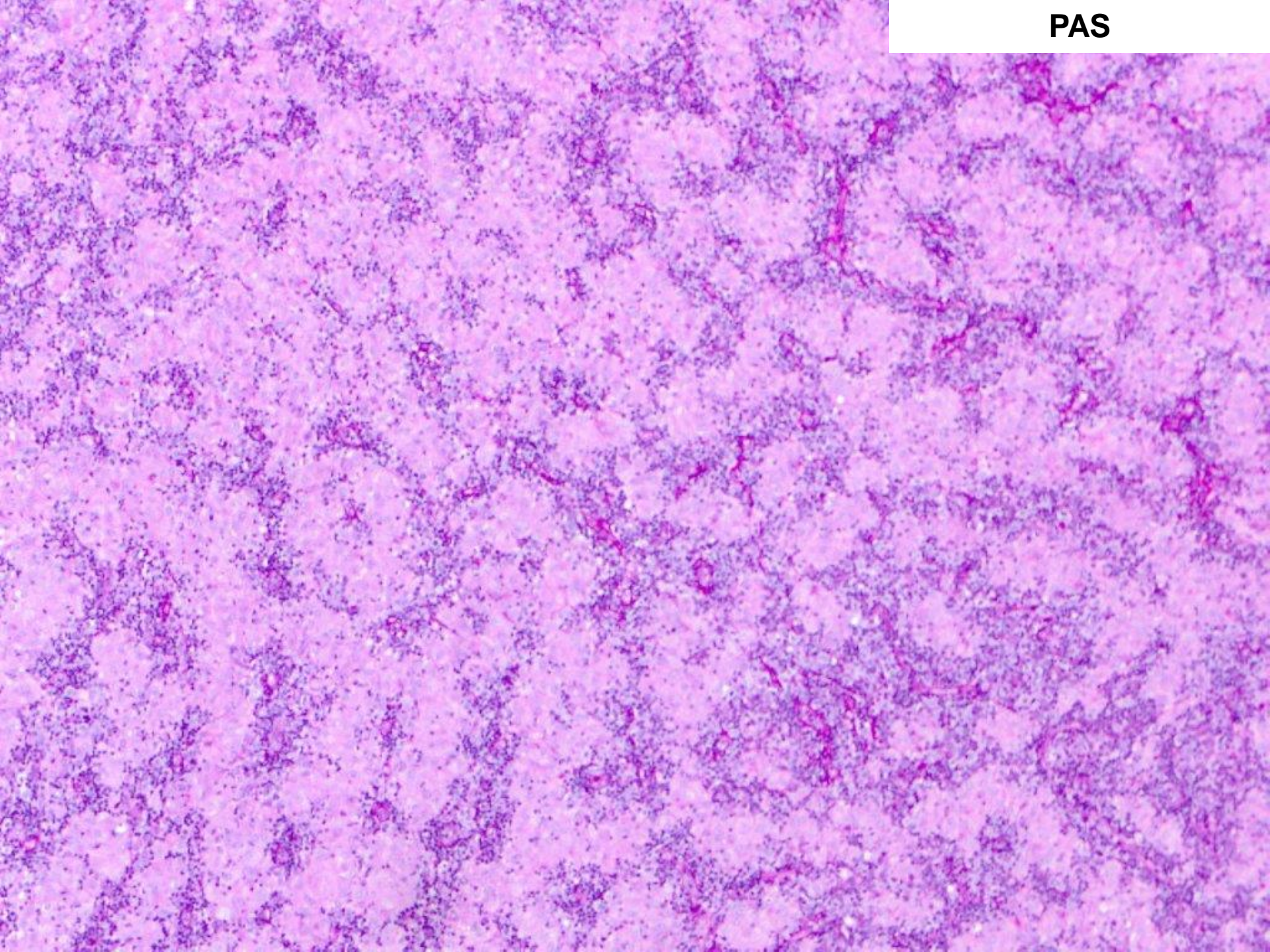
H+E



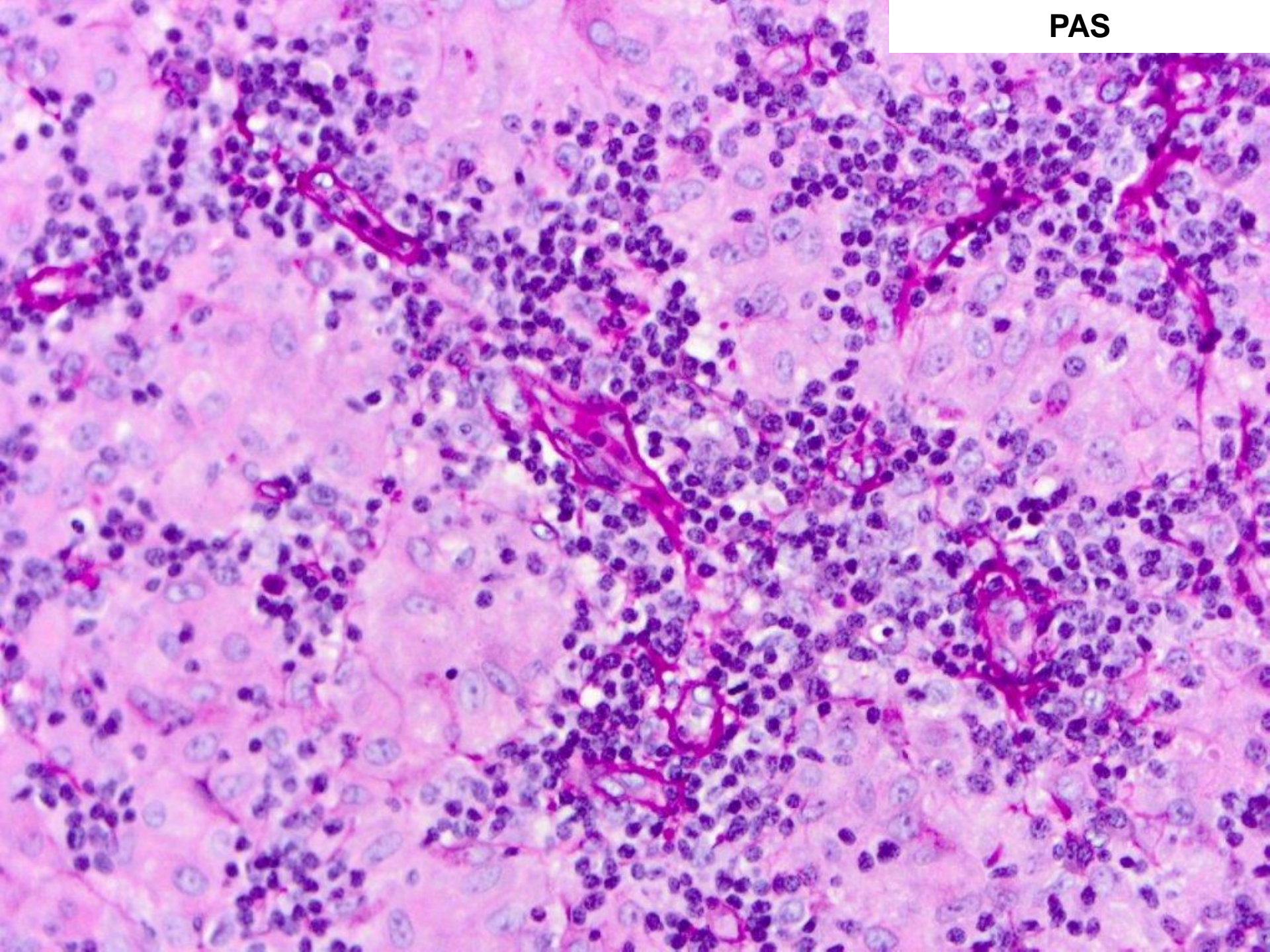
H+E

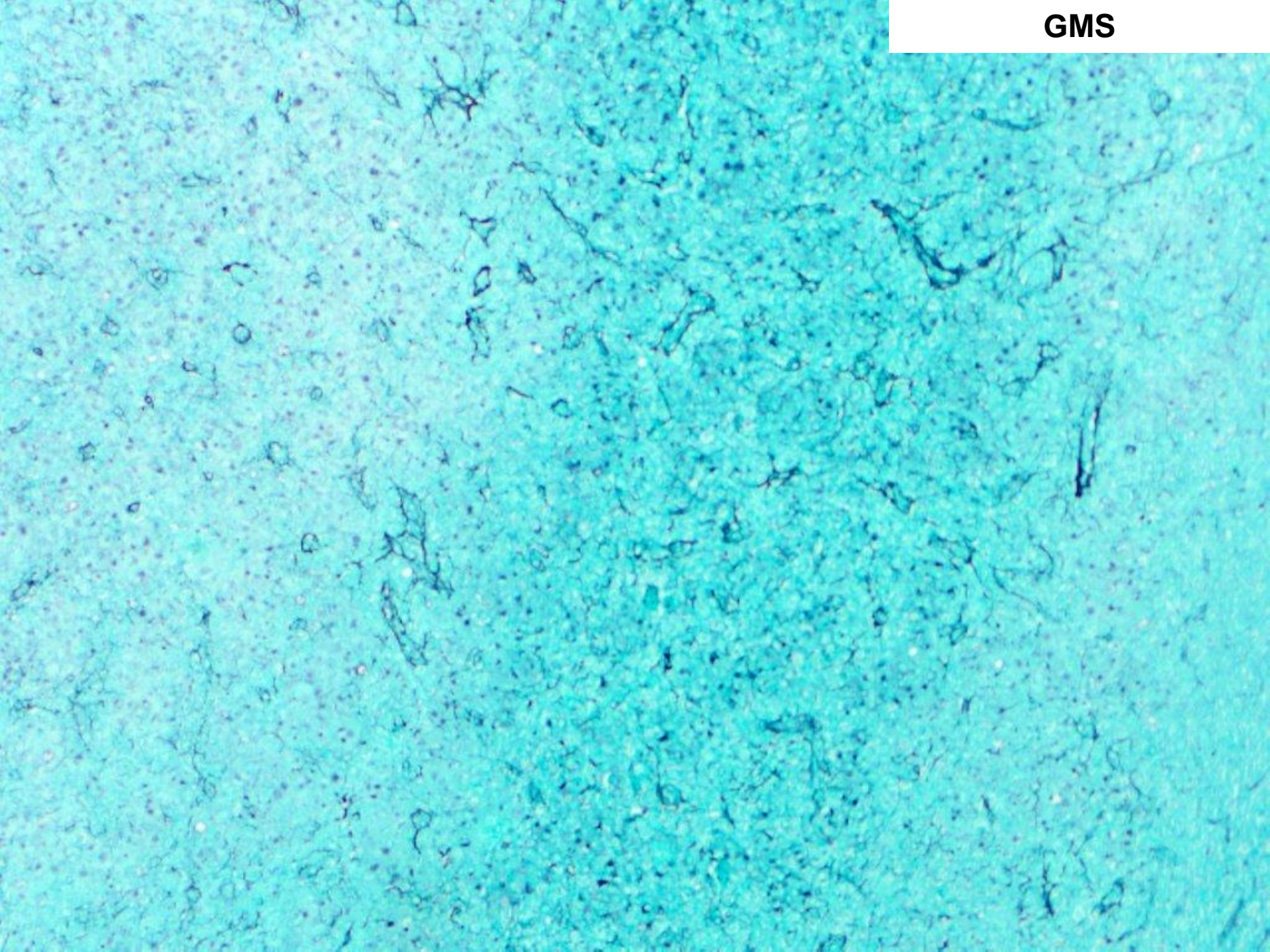


PAS




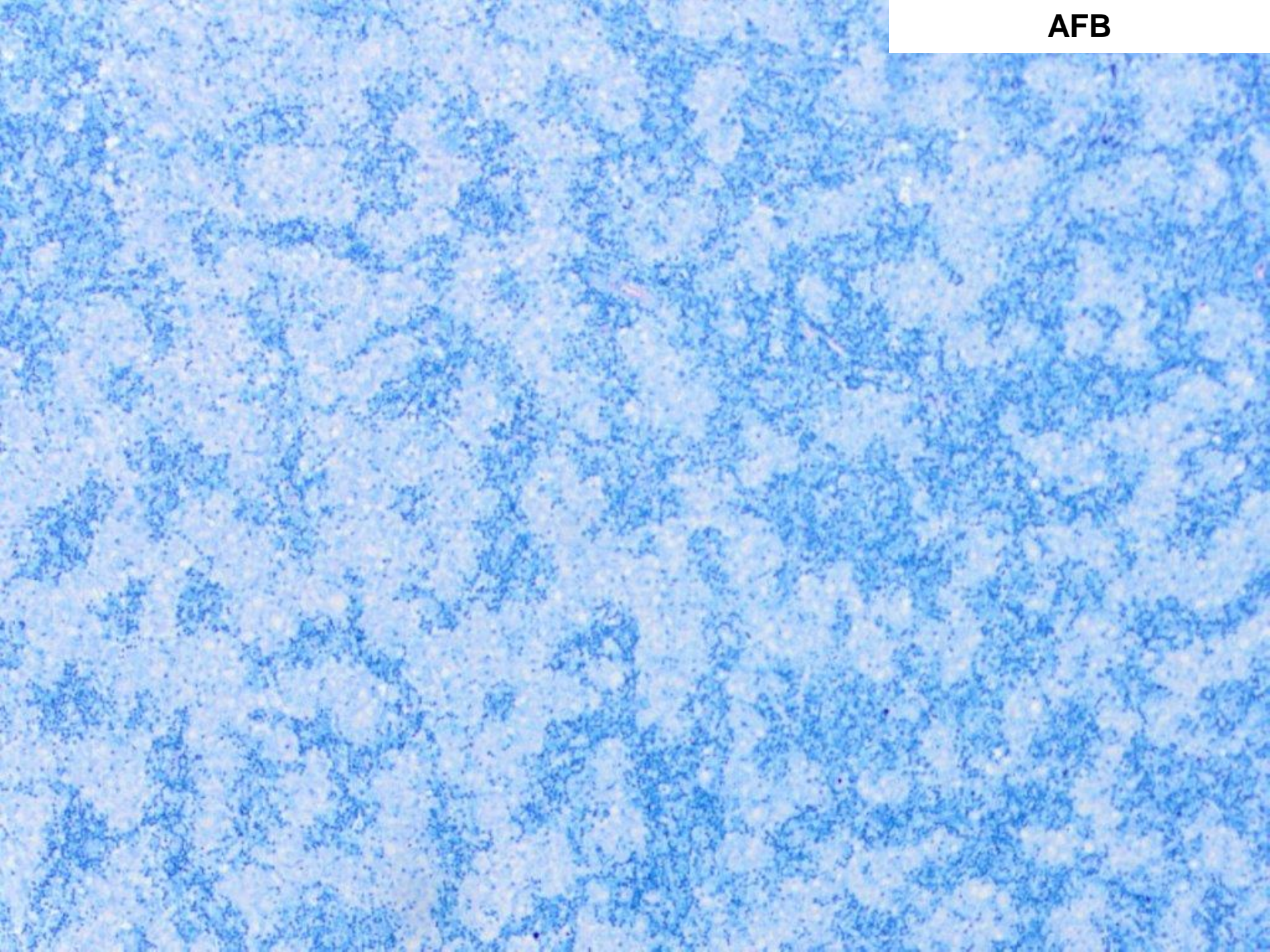
PAS



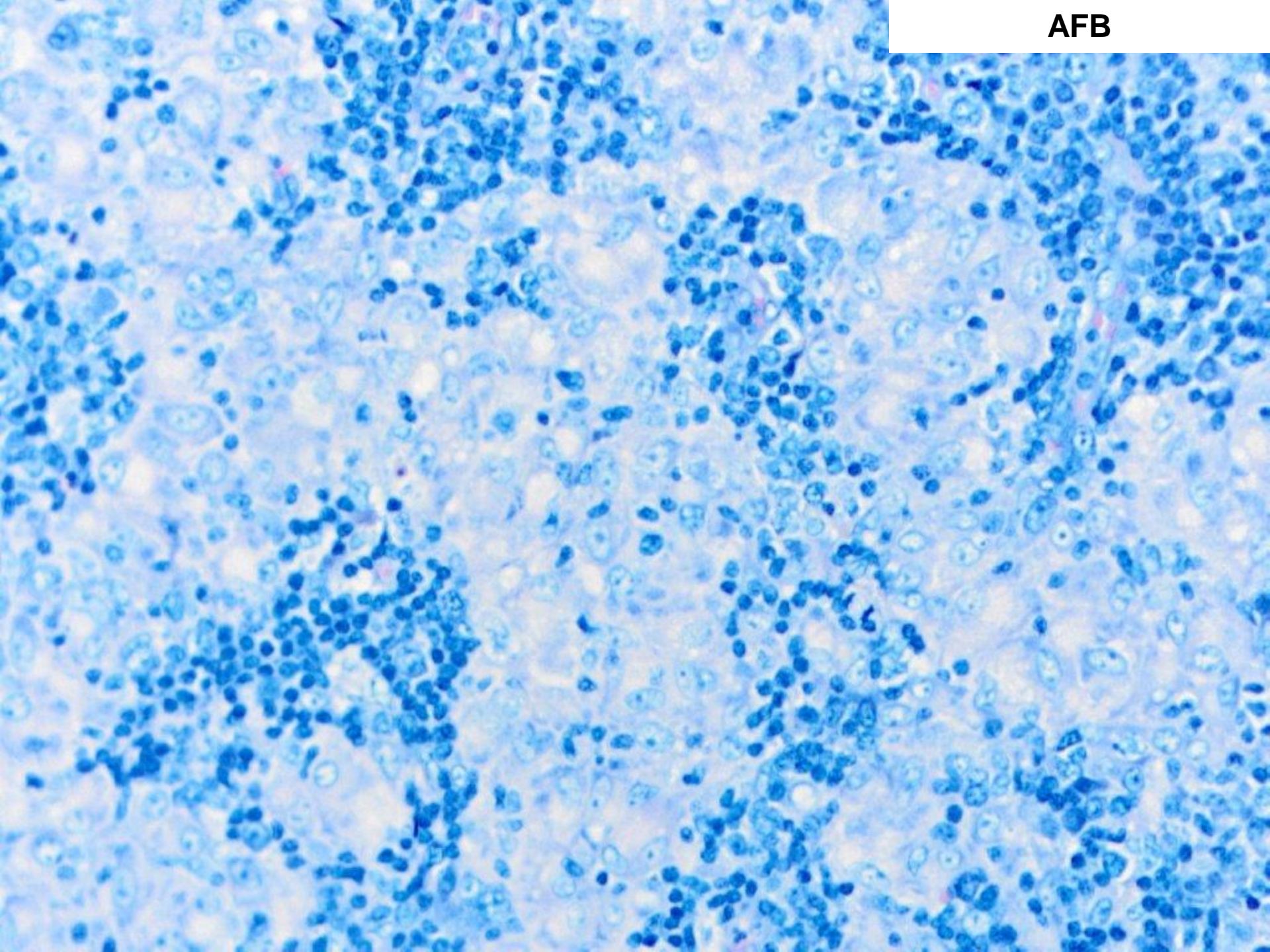


GMS

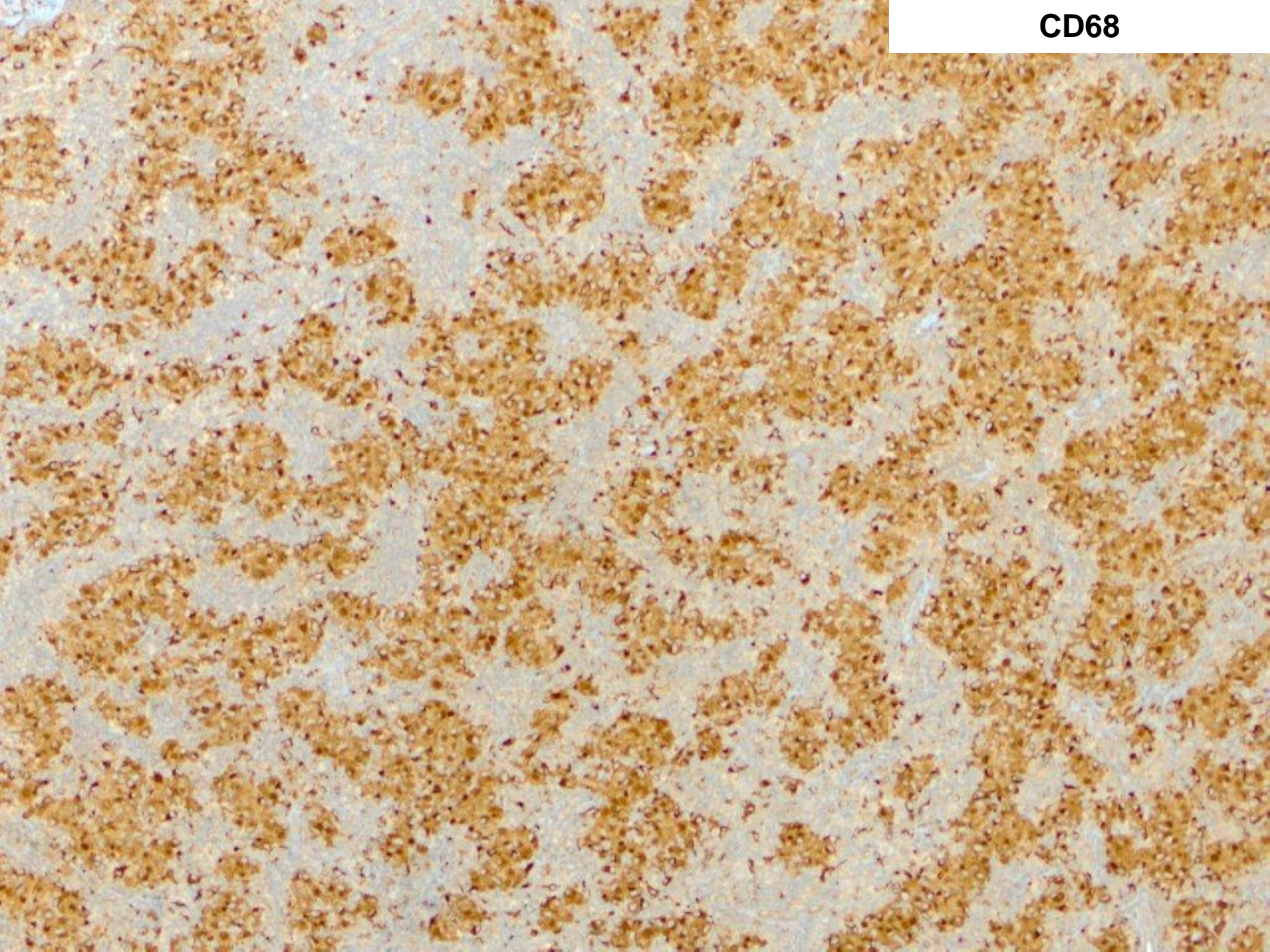




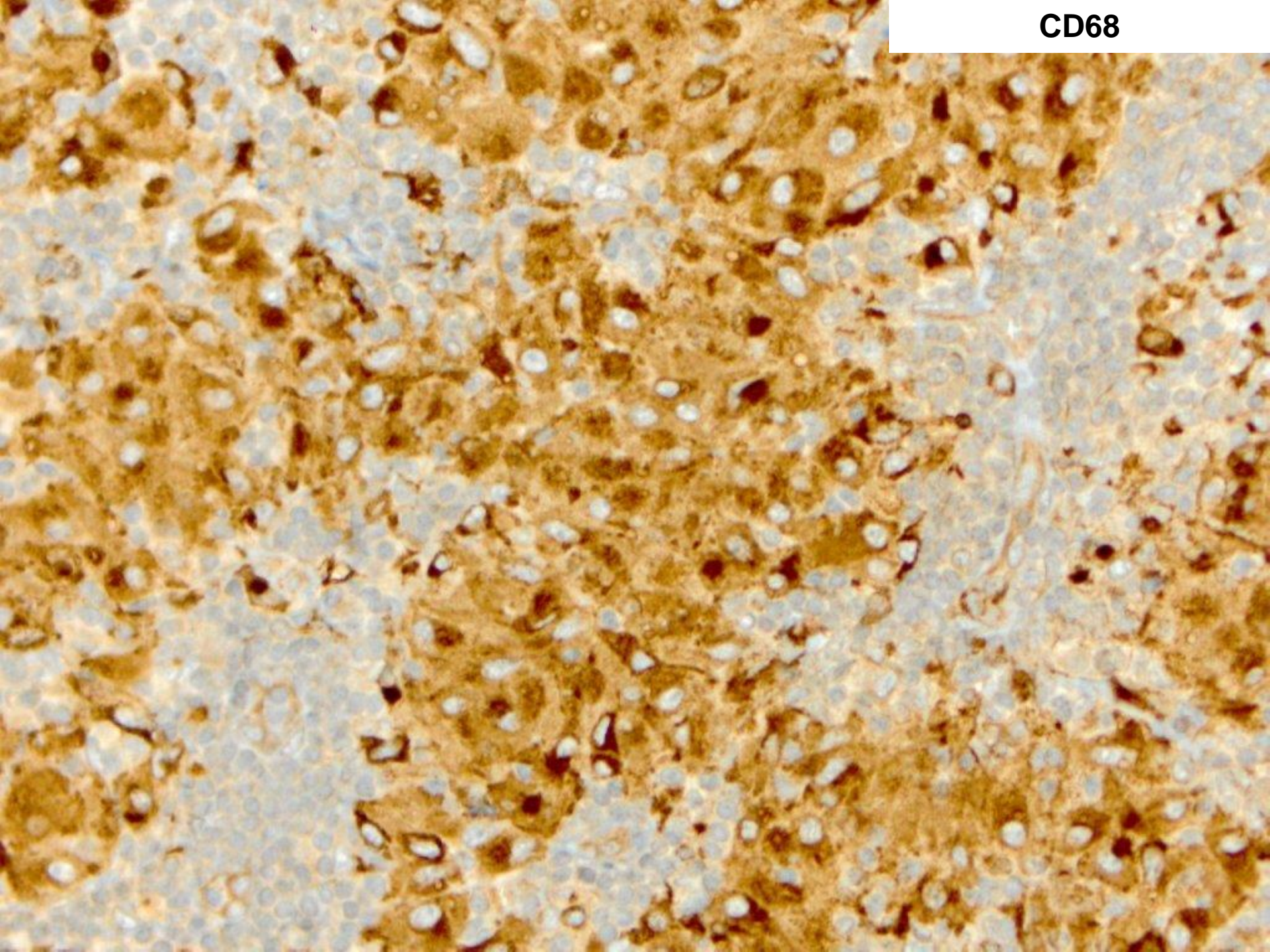
AFB



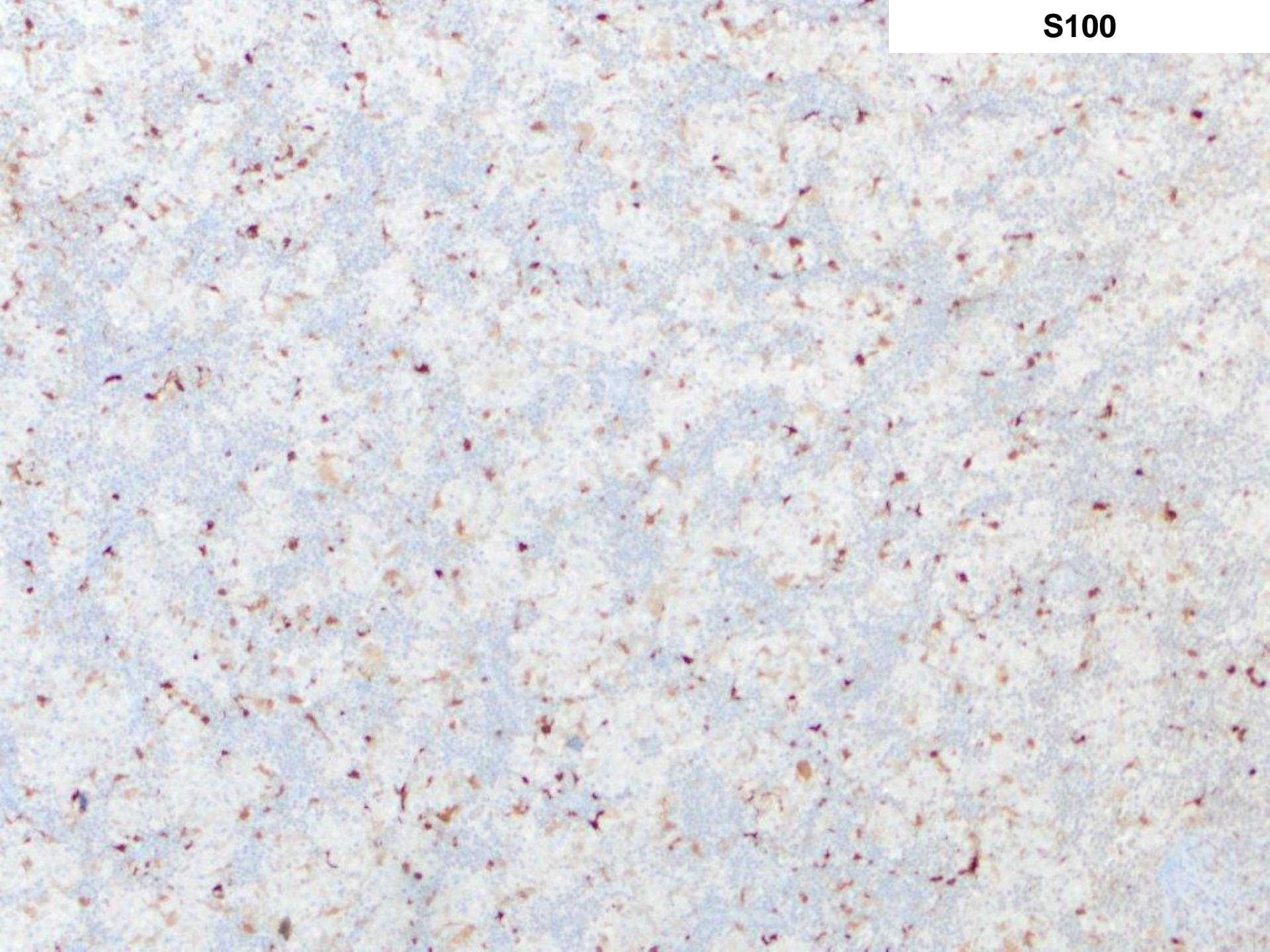
CD68



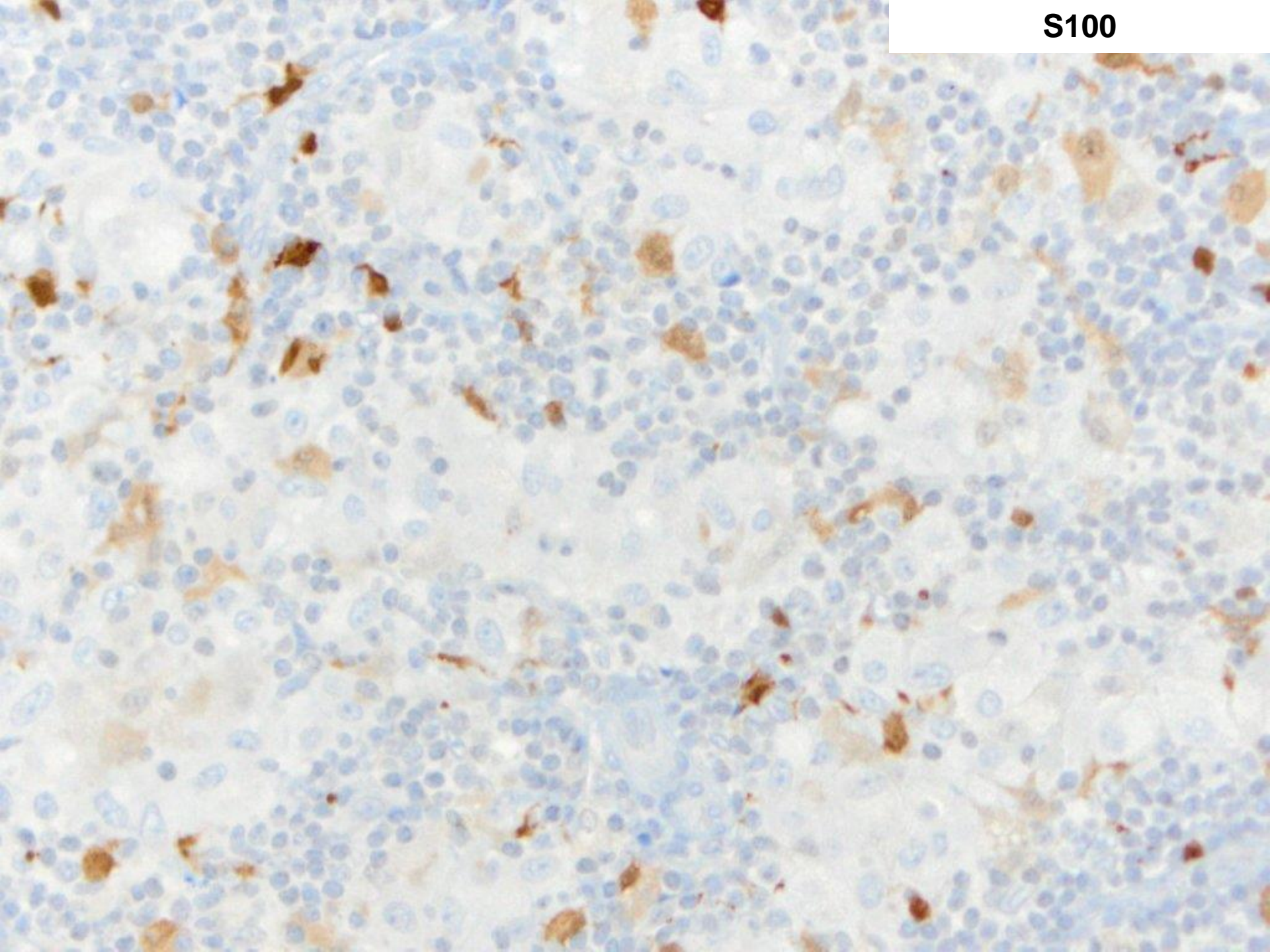
CD68



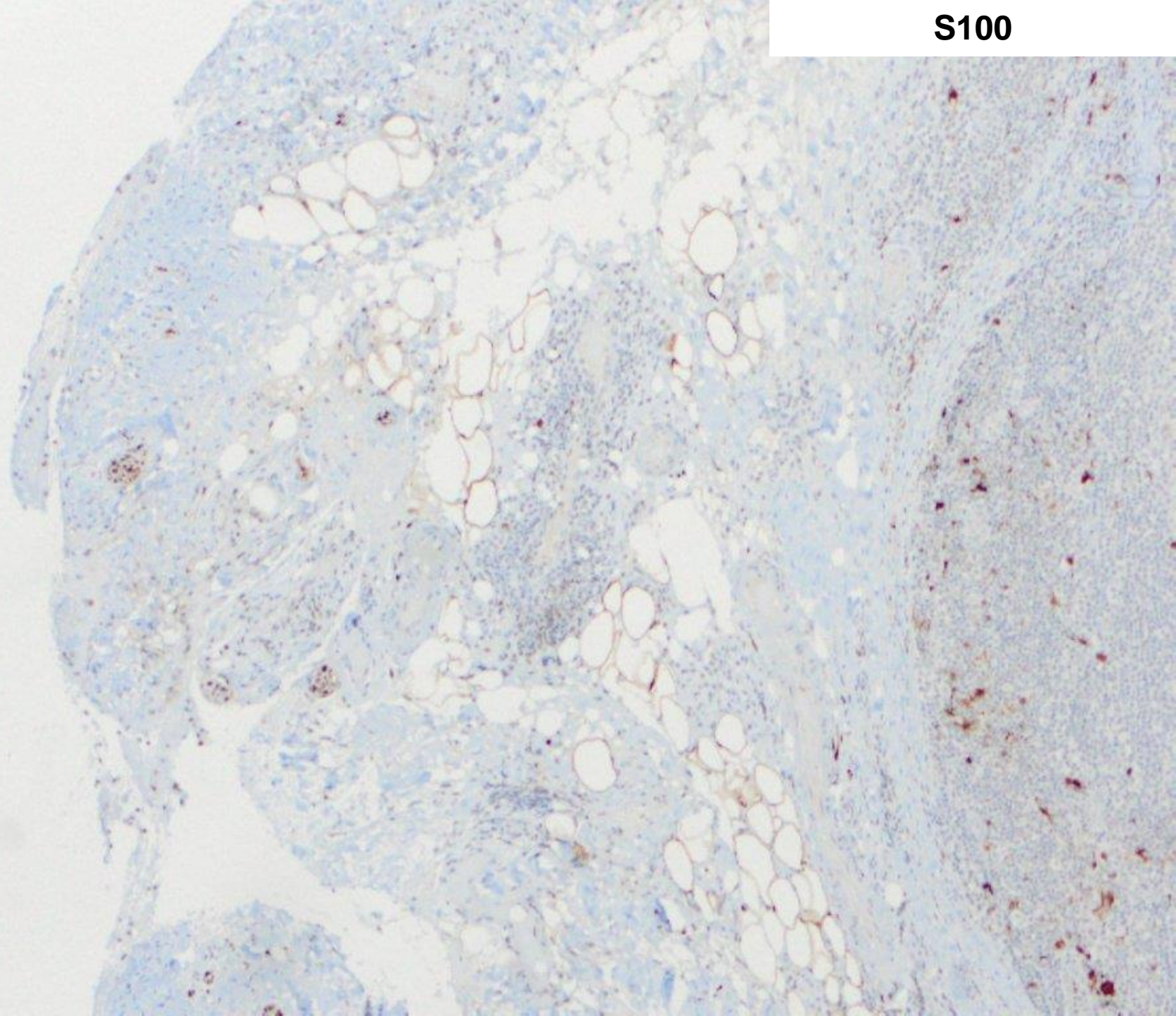
S100



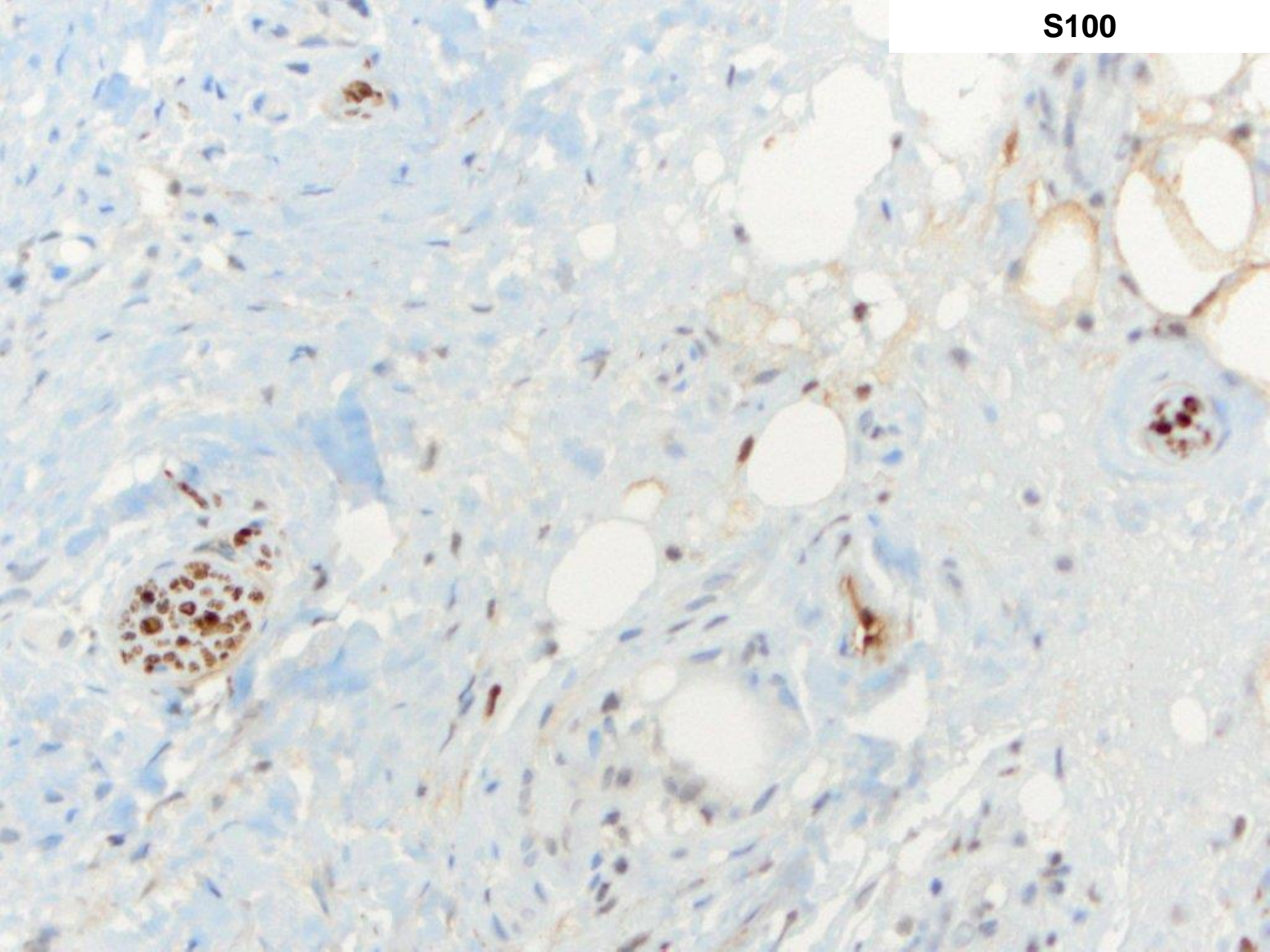
S100



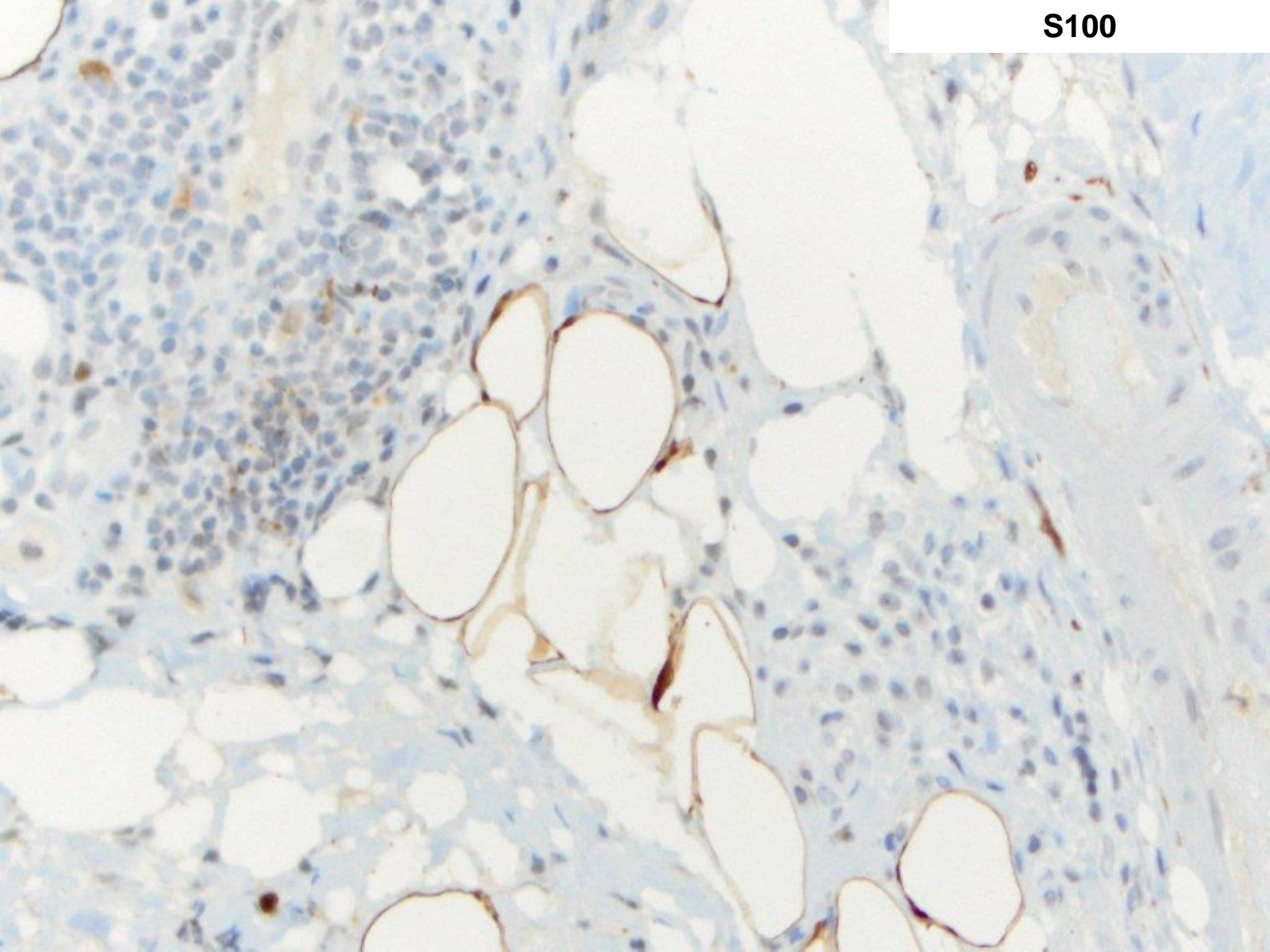
S100

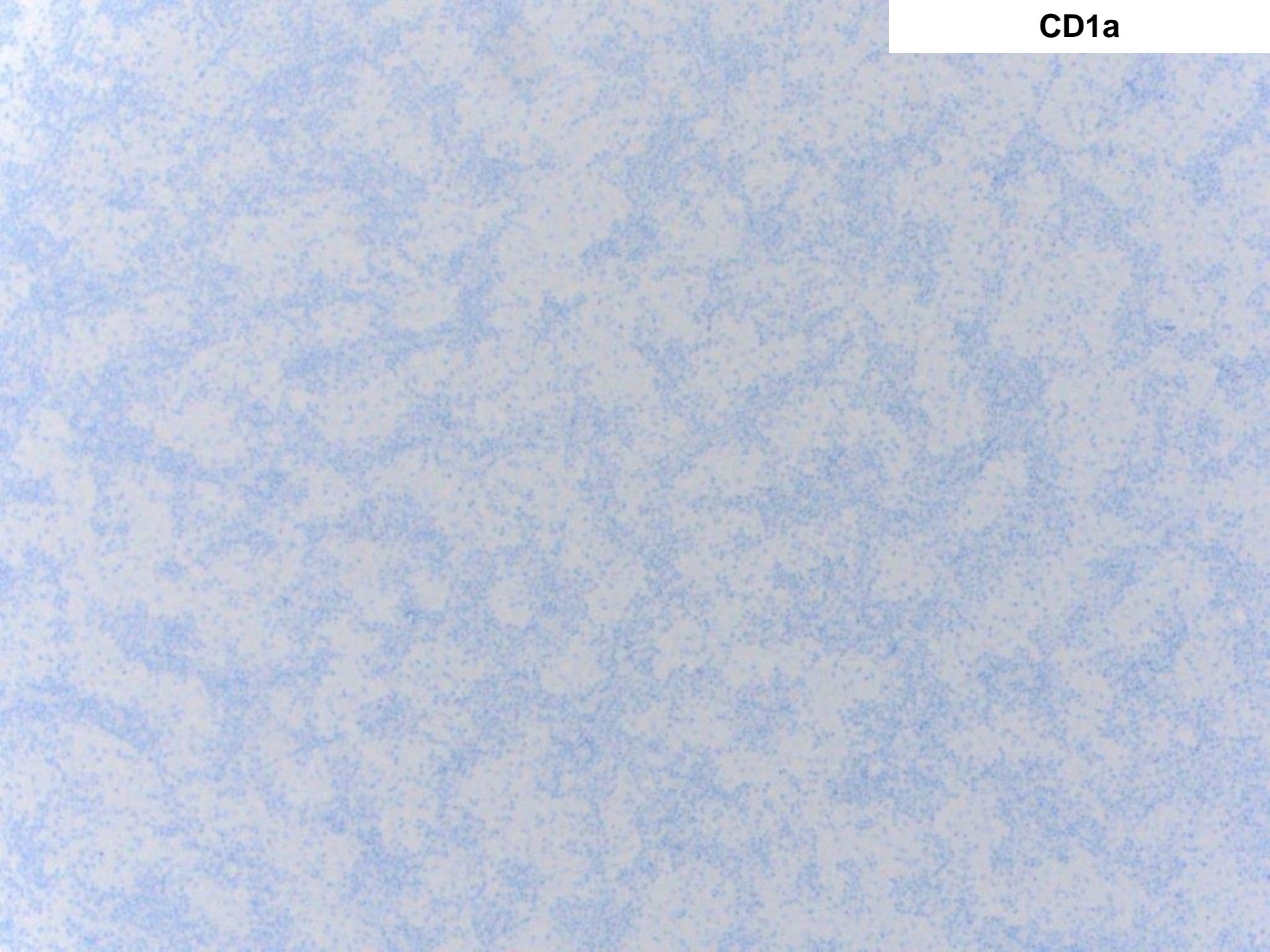


S100

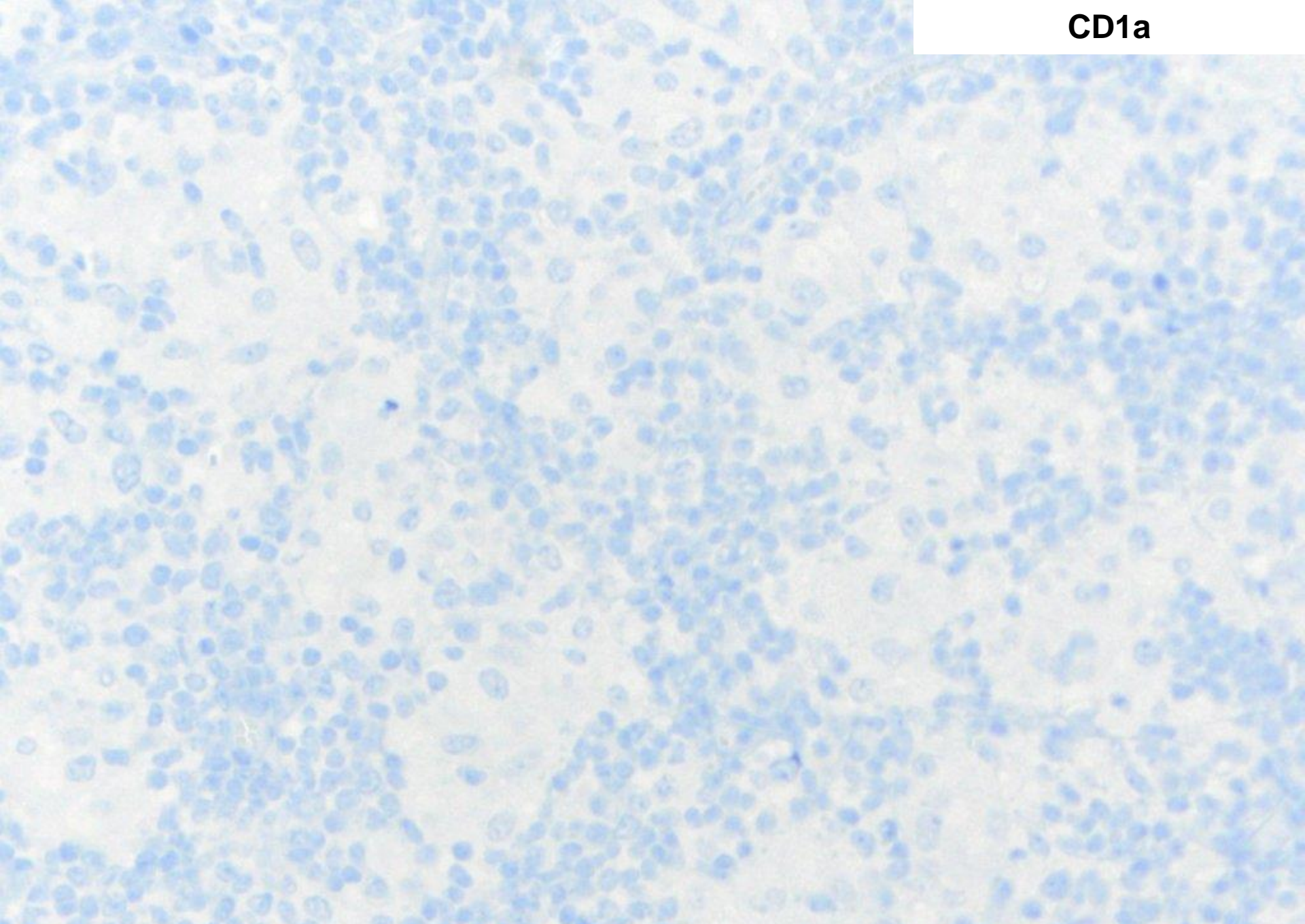


S100





CD1a



reactive lymph node with granulomas consisting of histiocytes